

Classification of Tendon Matrix Change Using Ultrasound Imaging: A Systematic Review and Meta-analysis

Matthews, Wesley; Ellis, Richard; Furness, James; Hing, Wayne A

Published in:
Ultrasound in Medicine and Biology

DOI:
[10.1016/j.ultrasmedbio.2018.05.022](https://doi.org/10.1016/j.ultrasmedbio.2018.05.022)

Published: 01/10/2018

Document Version:
Peer reviewed version

Licence:
CC BY-NC-ND

[Link to publication in Bond University research repository.](#)

Recommended citation(APA):

Matthews, W., Ellis, R., Furness, J., & Hing, W. A. (2018). Classification of Tendon Matrix Change Using Ultrasound Imaging: A Systematic Review and Meta-analysis. *Ultrasound in Medicine and Biology*, 44(10), 2059-2080. <https://doi.org/10.1016/j.ultrasmedbio.2018.05.022>

General rights

Copyright and moral rights for the publications made accessible in the public portal are retained by the authors and/or other copyright owners and it is a condition of accessing publications that users recognise and abide by the legal requirements associated with these rights.

For more information, or if you believe that this document breaches copyright, please contact the Bond University research repository coordinator.

Classification of tendon matrix change using ultrasound imaging: A systematic review and meta-analysis

Authors

Wesley Matthews^a, Richard Ellis^b, James Furness^a and Wayne Hing^a

Author Affiliations

^a Bond Institute of Health and Sport, Faculty of Health Sciences and Medicine, Bond University, Robina, Gold Coast, Queensland, Australia.

^b Health and Rehabilitation Research Institute, School of Clinical Sciences, Auckland University of Technology, Auckland, New Zealand.

Corresponding Author

Wesley Matthews

44/68-74 Liverpool Road

Summer Hill

New South Wales

Australia 2130

Email: wesley.matthews@student.bond.edu.au

Phone: +61 406 756 472

Abstract

Ultrasound imaging (US) is an accurate and reliable method used to diagnose tendinopathy. This systematic review aimed to identify common criteria and parameters used to diagnose tendinopathy, the methodological quality of studies, and the predictive value of US. Nineteen studies met the inclusion criteria, with the Achilles, quadriceps and patella tendons being investigated. Overall, there was significant heterogeneity between the criteria used to diagnose tendinopathy utilising US. The methodological quality of included studies was "good". Additionally, meta-analysis showed that US identified abnormalities were predictive of future symptoms, and classification of tendinopathy using three US defined parameters demonstrated a higher relative risk of developing clinical tendinopathy when compared to using two US defined parameters. Further research into the development of a standardised US criterion that incorporates both clinical and US findings is required to allow for greater consistency in the diagnosis of tendinopathy.

Keywords

Ultrasound imaging, tendinopathy, diagnosis, classification

1 **Introduction**

2

3 Tendinopathy is an umbrella term for the clinical presentation of tendon pain
4 and dysfunction with accompanying presumed pathological structural change to the
5 internal tendon matrix (Maffulli, et al. 1998, Plinsinga, et al. 2015, Rees, et al. 2009).
6 It is frequently seen in clinical practice, with the most commonly affected tendons
7 being the Achilles, patellar, rotator cuff and elbow extensors (McCreesh and Lewis
8 2013, Rees, et al. 2009). Overuse tendon injuries account for 30-50% of all sports
9 injuries (Scott and Ashe 2006). The catalyst for the onset of tendinopathy can be
10 due to both an increase (Ackermann and Renström 2012, Lewis 2009, Maffulli, et al.
11 1998, Rio, et al. 2014, Scott, et al. 2015) and a decrease (Arnoczky, et al. 2007,
12 Reeves, et al. 2005) in mechanical loading of the tendon. It is chronic in nature, with
13 recovery ranging from 3-14 months (Bonde, et al. 2003, Khan, et al. 2000). Similarly,
14 studies have shown that a minimum of 6-months is required to see significant
15 structural change on imaging (de Vos, et al. 2011, Ryan, et al. 2010, Ryan, et al.
16 2011). Although, there is some evidence that structural changes can be seen on
17 imaging in a shorter time-frame (Docking, et al. 2016).

18

19 There have been alternate models to describe the pathogenesis of
20 tendinopathy (Abate, et al. 2009, Arnoczky, et al. 2007, Cook and Purdam 2009, Fu,
21 et al. 2010). Of these models, the continuum model of tendinopathy, as originally
22 proposed by Cook and Purdam (Cook and Purdam 2009), has become a widely
23 accepted theoretical base and method to stage tendinopathy (Cook and Purdam
24 2009, Cook, et al. 2016, McCreesh and Lewis 2013, Rees, et al. 2014). The stages

1 identified within this model are distinguished by specific clinical and imaging features
2 (Cook, et al. 2016).

3

4 There are two primary methods for the diagnosis of tendinopathy (Scott, et al.
5 2013). Clinically, the diagnosis of tendinopathy is predominantly centred on the
6 patient history and clinical examination (Coombes, et al. 2015, Lewis 2016, Lewis, et
7 al. 2015, Malliaras, et al. 2015, Scase, et al. 2011, Scott, et al. 2013). In regard to
8 specific tests that have been reported to aid the diagnosis of tendinopathy, two out of
9 ten commonly used tests (pain on palpation and location of pain) were found to be
10 sufficiently reliable and accurate when compared to ultrasound imaging (Hutchison,
11 et al. 2013). While pain on palpation has been shown to be sensitive (56-84%) for
12 reproducing clinical symptoms, it is not specific (47-73%) in identifying pathological
13 structural change when compared to medical imaging (Cook, et al. 2001, Grimaldi, et
14 al. 2017, Hutchison, et al. 2013). Furthermore, clinical tests alone do not allow
15 clinician the ability to determine where their patient may be on the tendinopathy
16 continuum as stages are primarily based off structural changes (Cook, et al. 2016).

17

18 Imaging presents a method where structural changes within the tendon matrix
19 can be identified. Both ultrasound imaging (US) and magnetic resonance imaging
20 (MRI) are used to confirm the presence of structural tendon change in the clinical
21 setting, with the choice of which technique to use based on clinician preference
22 (Scott, et al. 2013). Furthermore, US has demonstrated better accuracy (Khan, et al.
23 2003, Warden, et al. 2007), and sensitivity (Westacott, et al. 2011) when compared
24 to MRI for assessing tendinopathy. Additionally, US has been shown to have good
25 reliability (Ingwersen, et al. 2016) and is considered more patient-friendly and cost

1 effective than MRI for the assessment of musculoskeletal conditions, with the ability
2 for dynamic assessment and the measurement of neovascularisation (Lento and
3 Primack 2008, Mapes-Gonnella 2013).

4

5 Although numerous studies have examined the sensitivity and accuracy of
6 imaging in identifying tendinopathy (Docking, et al. 2015, Scott, et al. 2013),
7 research utilising US has been limited to classifying tendon structural change with
8 the use of subjective grading scores established on a multitude of pathological
9 features (Docking, et al. 2015, Ellis and Manuel 2015). In a recent literature review
10 (Ellis and Manuel 2015), the most commonly reported abnormal tendon matrix
11 features, as seen with US, included echogenicity, fusiform swelling, tendon
12 thickness, neovascularisation, fibrillation, calcification and intra-substance tears.

13

14 It has been proposed that abnormalities identified on US may be considered
15 as a risk factor for the development of future symptoms (Cook, et al. 2016, McAuliffe,
16 et al. 2016). However, due to the cross-sectional design of many imaging studies
17 (McAuliffe, et al. 2016) and the variability in features measured (Ellis and Manuel
18 2015), uncertainty remains as to the relevance of identified tendon structural
19 abnormalities and their impact on the management of tendinopathy in populations
20 where there is a high prevalence of tendon related pain (McAuliffe, et al. 2016).

21 Although it is accepted that US identified tendon abnormalities can be considered a
22 risk factor (Cook, et al. 2016, McAuliffe, et al. 2016), no study has investigated the
23 predictability of varying classification systems utilising different US based
24 parameters.

25

1 The lack of a homogenous and standardised US criterion for assessing
2 tendon matrix change makes determining the clinical utility of US in the diagnosis
3 and management of tendinopathy difficult. Identification of commonly used US
4 parameters and classification systems, along with assessing the predictability of
5 varying parameters, may aid in determining the clinical utility of US and lead to
6 greater homogeneity within this topic area. Thus, the primary aim of this systematic
7 review was to identify the US based tendinopathy classifications that are reported,
8 including specific tendon matrix features measured. Following this review, the
9 secondary aim was to appraise the methodological quality of the included studies.
10 The final aim was to utilise meta-analysis to assess the predictive value of the
11 different classification systems that were identified.

12

13 **Methods**

14

15 *Study Design*

16

17 The study followed the methodology proposed in the Preferred Reporting
18 Items for Systematic Reviews and Meta-Analysis (PRISMA) statement (Moher, et al.
19 2009). Following the PRISMA guidelines, a detailed search strategy was developed
20 and implemented up to August 2017.

21

22 *Eligibility Criteria*

23

24 Studies were included if they met the following criteria:

- 25 • Published full-length research articles in English with the full text available

- 1 • Human participants (male or female) of any age, from any athletic or
2 community background
- 3 • Longitudinal (randomised or non-randomised) or observational
4 (retrospective or prospective) study design
- 5 • Minimum clinical follow-up over 24 hours as tendons demonstrate an
6 immediate response to load on imaging (Koenig, et al. 2010, Rosengarten,
7 et al. 2015)
- 8 • Tendinopathy in any location
- 9 • US as an outcome measure to assess tendon matrix changes (e.g. tendon
10 thickness, echogenicity, collagen organisation, fibrillar pattern,
11 vascularisation, etc.)
- 12 • Graded or classified tendinopathy stage using either a nominal or ordinal
13 scale

14

15 Studies were excluded if they met the following criteria:

- 16 • Patients who had other medical conditions that may affect outcome
17 measures (e.g. Rheumatoid arthritis, diabetes mellitus)
- 18 • Cross-sectional studies
- 19 • Focused on tendon tear or rupture
- 20 • Surgical interventions or injection therapies (corticosteroid or platelet
21 rich plasma) as part of the treatment protocol

22

23 *Search Methods*

24

1 A detailed, multi-step search strategy using PRISMA guidelines, was
2 conducted up to August 2017 to identify relevant studies regardless of publication
3 date. The search was conducted in the following databases: Embase; PubMed;
4 SPORTDiscus; EBSCOhost; CINAHL; ProQuest. In addition to the electronic
5 database search, included articles reference lists were searched for additional
6 articles. To ensure a wider search strategy of relevant articles, keywords were
7 truncated to allow for variations in spelling, and combined using Boolean operators
8 as outlined in Table 1. MeSH terms were also used to ensure review of relevant
9 articles. Search strategies for databases were equivalent with the same keywords
10 and Boolean operators, however slight adaptations were made depending on each
11 databases' respective characteristics.

12

13 *Study Selection*

14

15 Search results were imported to EndNote reference management software
16 (EndNote X8.0.1, Clarivate Analytics, 22 Thomson Place, 36T3 Boston, MA 02210).
17 Duplicate records were removed. Titles and abstracts of retrieved articles were
18 screened for eligibility. After the initial screening, the full-text of relevant studies were
19 retrieved for further analysis.

20

21 *Data Extraction*

22

23 Data extracted included specific details regarding the study design, authors,
24 year of publication, population, intervention methodology, tendon location and length

1 of follow-up. Specific data related to outcome measures included parameters
2 measured and grading or classification system used.

3

4 *Assessment of Methodological Quality*

5

6 The Critical Appraisal Skills Programme (CASP) tool was used to assess
7 methodological quality of included studies (Critical Appraisal Skills Programme 2017,
8 Critical Appraisal Skills Programme 2017). Studies were assessed using the CASP
9 toolkit independently by two researchers (WM and JF). The CASP toolkit is
10 comprised of eight separate checklists to be used depending on study design and
11 enables researchers to critically assess the validity and relevance of published
12 articles. The included articles were assessed for quality using the CASP Cohort
13 Study Checklist (Critical Appraisal Skills Programme 2017) and the CASP
14 Randomised Controlled Trial Checklist (Critical Appraisal Skills Programme 2017).
15 The CASP Cohort Study Checklist (Critical Appraisal Skills Programme 2017)
16 provides 12 questions to assess study quality. The first two questions are screening
17 questions, while the next ten provide a framework to assess the results of the study,
18 the study validity and relevance. Similarly, the CASP Randomised Controlled Trial
19 Checklist (Critical Appraisal Skills Programme 2017) uses 11 questions to assess
20 validity, results and applicability of studies, with the first two questions being
21 screening questions.

22

23 As was the method of a recent systematic review (McAuliffe, et al. 2016),
24 questions seven, eight and nine in the CASP Cohort Study Checklist (Critical
25 Appraisal Skills Programme 2017) and questions seven and eight in the CASP

1 Randomised Controlled Trial Checklist (Critical Appraisal Skills Programme 2017)
2 were combined into one question, as they were deemed to investigate similar areas.
3 Most questions are answered with 'yes', 'no' or 'can't tell'. The CASP checklists do
4 not provide a scoring system to appraise the quality of evidence (Critical Appraisal
5 Skills Programme 2017, Critical Appraisal Skills Programme 2017). However,
6 although there is a lack of consensus as to what criteria to appraise in quantitative
7 research, it is recognised that quality issues should be highlighted by reviewers
8 (Goldsmith, et al. 2007). For the purpose of this systematic review, a scoring system
9 was developed where '1' point was awarded for a 'yes' and '0' points for a 'no', with
10 the maximum score being 12 for the CASP Cohort Study Checklist (Critical Appraisal
11 Skills Programme 2017) and 10 for the CASP Randomised Controlled Trial Checklist
12 (Critical Appraisal Skills Programme 2017).

13

14 Overall scores were calculated as a percentage and quality was rated
15 according to the methods reported by Kennelly (2011) where grades were
16 categorized as 'poor', 'fair' or 'good'. Studies that scored $\geq 60\%$ were considered as
17 'good' quality, while studies that scored between 45%-59% were 'fair' and studies
18 that scored $< 45\%$ were considered 'poor', as has been reported in previous studies
19 (Adhia, et al. 2013, Barrett, et al. 2014, May, et al. 2010, May, et al. 2006). To
20 ensure consistency of critical appraisal, the criteria used for each question in the
21 CASP checklist was agreed upon between the two reviewers (WM and JF) prior to
22 commencement of the appraisal process. Inter-rater agreement for each question
23 and overall was calculated using Cohen's Kappa coefficient.

24

25 *Synthesis and Analysis*

1
2
3
4
5
6
7
8
9
10
11
12
13
14
15
16
17
18
19
20
21
22
23
24
25

To determine agreement between raters following the critical appraisal process, a Cohen's Kappa was calculated using SPSS software package (IBM SPSS Statistics for Macintosh, Version 24.0. Armonk, NY: IBM Corp.). Where quantitative methods were appropriate to statistically pool data, a meta-analysis was performed using Review Manager software (Review Manger (RevMan) for Macintosh, Version 5.3. Copenhagen: The Nordic Cochrane Centre, The Cochrane Collaboration, 2014). A random effects models using the Mantel-Haenszel method was used to determine pooled relative risk (RR) of developing symptomatic tendinopathy with 95% confidence intervals (CI). Studies were included in the meta-analysis if they used similar methodology, reported on asymptomatic tendons that became symptomatic, and provided data on asymptomatic baseline structural changes and development of symptoms at follow-up. Studies were excluded from the meta-analysis if they included symptomatic tendons from baseline, used specific interventions as part of the rehabilitation process, or provided insufficient data on baseline or follow-up structural changes. RR was calculated for three subgroups; 1) tendon site (Achilles or patellar), 2) number of parameters used in classifications (3 parameters or 2 parameters), and 3) number of parameters used for specific tendon location.

The heterogeneity between studies was assessed using the I^2 statistic. The I^2 value describes the percentage of variation across the studies that is due to heterogeneity rather than chance, ranging from 0-100%, where 0% shows no heterogeneity and increasing values show increasing heterogeneity (Higgins, et al. 2003). I^2 values of 25% indicate low, 50% moderate and 75% high heterogeneity

1 (Higgins, et al. 2003). Similar to a previous systematic review (Smidt, et al. 2003), a
2 RR >1.5 was considered clinically significant for the predictability of US identified
3 abnormalities in asymptomatic tendons becoming symptomatic. RR was summarised
4 using forest plots, while study and publication bias was assessed using funnel plots.
5

6 Where meta-analysis was not appropriate due to the heterogeneity of articles
7 and criterion used to assess tendon matrix change on US, a qualitative approach
8 was utilized. Results were synthesised to analyse tendon parameters measured,
9 quality of evidence, predictive value of criteria and relationship to the continuum
10 model of tendinopathy. This data synthesis was then used to inform and guide the
11 development of the proposed criteria, with a greater weighting being placed on
12 articles of 'good' quality and parameters that were predictive of tendinopathy.
13

14 **Results**

16 *Search Results*

17
18 The search results are shown in the PRISMA Flow Diagram (Figure 1). After
19 the removal of duplicates and screening of titles and abstracts against the inclusion
20 criteria, the full-text of 68 articles was retrieved and assessed for inclusion in the
21 systematic review. Of these, nineteen articles (Archambault, et al. 1998, Boesen, et
22 al. 2012, Comin, et al. 2013, Cook, et al. 2001, Cook, et al. 2000, de Jonge, et al.
23 2010, de Vos, et al. 2007, Fredberg and Bolvig 2002, Fredberg, et al. 2008,
24 Giombini, et al. 2013, Gisslén and Alfredson 2005, Gisslén, et al. 2007, Hirschmüller,
25 et al. 2012, Jhingan, et al. 2011, Khan, et al. 1997, Khan, et al. 2003, Malliaras, et al.

1 2010, Ooi, et al. 2015, Visnes, et al. 2015) met the inclusion criteria and were
2 included in the systematic review.

3

4 *Characteristics of Included Studies*

5

6 A detailed description of the included studies is provided in Table 2. Of the
7 nineteen included studies, seventeen were cohort studies (Archambault, et al. 1998,
8 Boesen, et al. 2012, Comin, et al. 2013, Cook, et al. 2001, Cook, et al. 2000, de Vos,
9 et al. 2007, Fredberg and Bolvig 2002, Giombini, et al. 2013, Gisslén and Alfredson
10 2005, Gisslén, et al. 2007, Hirschmüller, et al. 2012, Jhingan, et al. 2011, Khan, et al.
11 1997, Khan, et al. 2003, Malliaras, et al. 2010, Ooi, et al. 2015, Visnes, et al. 2015)
12 and two were randomised controlled trials (de Jonge, et al. 2010, Fredberg, et al.
13 2008). While no limitations were placed on tendon location, all nineteen included
14 studies investigated tendons in the lower limb, with the Achilles, patellar and
15 quadriceps tendons assessed (Archambault, et al. 1998, Boesen, et al. 2012, Comin,
16 et al. 2013, Cook, et al. 2001, Cook, et al. 2000, de Jonge, et al. 2010, de Vos, et al.
17 2007, Fredberg and Bolvig 2002, Fredberg, et al. 2008, Giombini, et al. 2013,
18 Gisslén and Alfredson 2005, Gisslén, et al. 2007, Hirschmüller, et al. 2012, Jhingan,
19 et al. 2011, Khan, et al. 1997, Khan, et al. 2003, Malliaras, et al. 2010, Ooi, et al.
20 2015, Visnes, et al. 2015). Tendon matrix change was classified using either a
21 nominal or ordinal scale. In a nominal scale, labels are descriptive, allowing for the
22 counting but not ordering of data, while an ordinal scale allows for data to be ranked
23 (Stevens 1946).

24

1 A nominal grading scale was used in twelve of the included studies (Comin, et
2 al. 2013, Cook, et al. 2001, Cook, et al. 2000, Fredberg and Bolvig 2002, Giombini,
3 et al. 2013, Gisslén and Alfredson 2005, Gisslén, et al. 2007, Hirschmüller, et al.
4 2012, Jhingan, et al. 2011, Khan, et al. 1997, Malliaras, et al. 2010, Visnes, et al.
5 2015), while an ordinal scale was used in the remaining seven studies (Archambault,
6 et al. 1998, Boesen, et al. 2012, de Jonge, et al. 2010, de Vos, et al. 2007, Fredberg,
7 et al. 2008, Khan, et al. 2003, Ooi, et al. 2015). The studies that used nominal scales
8 classified tendon structural change as either 'normal' or 'abnormal' (Comin, et al.
9 2013, Cook, et al. 2001, Cook, et al. 2000, Fredberg and Bolvig 2002, Giombini, et
10 al. 2013, Gisslén and Alfredson 2005, Gisslén, et al. 2007, Hirschmüller, et al. 2012,
11 Jhingan, et al. 2011, Khan, et al. 1997, Malliaras, et al. 2010, Visnes, et al. 2015).
12 Three studies that used an ordinal scale graded tendinopathy as 'Grade 1', 'Grade 2,
13 or 'Grade 3' (Archambault, et al. 1998, Khan, et al. 2003, Ooi, et al. 2015), while one
14 classified change as 'normal', 'slightly abnormal' or 'severely abnormal' (Fredberg, et
15 al. 2008). Two studies used a 5-point scale (de Jonge, et al. 2010, de Vos, et al.
16 2007) and one used a 6-point scale (Boesen, et al. 2012).

17

18 *Study Scoring and Quality*

19

20 Overall CASP results are summarised in Table 3. Inter-rater agreement was
21 calculated for each question using Cohen's Kappa. Overall, based on previously
22 published guidelines (Fleiss 1981), Cohen's Kappa was excellent at 0.93 for the
23 seventeen cohort studies and perfect at 1.00 for the two randomised controlled trials.
24 Disagreements were discussed, and a consensus drawn between the two raters.
25 The quality of all studies was rated as 'good' according to the categories proposed

1 by Kennelly (Kennelly 2011) and the criteria used in previous studies (Adhia, et al.
2 2013, Barrett, et al. 2014, May, et al. 2010, May, et al. 2006).

3

4 *Synthesis of Evidence*

5

6 A synthesis of evidence is provided in Table 4. Overall, there was significant
7 heterogeneity between the parameters used to assess tendon matrix change and the
8 ability to predict outcomes. Three studies (Boesen, et al. 2012, de Jonge, et al. 2010,
9 de Vos, et al. 2007) measured only one parameter when assessing tendon matrix
10 change, while six studies (Archambault, et al. 1998, Cook, et al. 2001, Cook, et al.
11 2000, Fredberg and Bolvig 2002, Fredberg, et al. 2008, Khan, et al. 1997) used two
12 parameters and the remaining ten studies (Comin, et al. 2013, Giombini, et al. 2013,
13 Gisslén and Alfredson 2005, Gisslén, et al. 2007, Hirschmüller, et al. 2012, Jhingan,
14 et al. 2011, Khan, et al. 2003, Malliaras, et al. 2010, Ooi, et al. 2015, Visnes, et al.
15 2015) used three parameters. No study included fibrillar pattern as a parameter to
16 assess tendon matrix change. All studies were of good quality according to the
17 previously stated scoring system. Additionally, no criteria were related to the stages
18 of tendinopathy as proposed in the Cook and Purdam (Cook and Purdam 2009)
19 continuum model. There were mixed results when looking at the predictive value of
20 the individual criterion, with nine studies (Boesen, et al. 2012, Comin, et al. 2013,
21 Cook, et al. 2001, de Jonge, et al. 2010, de Vos, et al. 2007, Hirschmüller, et al.
22 2012, Jhingan, et al. 2011, Khan, et al. 2003, Ooi, et al. 2015) indicating
23 abnormalities measured on US are unable to predict of clinical outcome, while the
24 remaining ten studies (Archambault, et al. 1998, Cook, et al. 2000, Fredberg and
25 Bolvig 2002, Fredberg, et al. 2008, Giombini, et al. 2013, Gisslén and Alfredson

1 2005, Gisslén, et al. 2007, Khan, et al. 1997, Malliaras, et al. 2010, Visnes, et al.
2 2015) showed US can be a predictor of clinical outcome.

3

4 *Echogenicity*

5

6 Echogenicity was the equal most commonly measured structural change on
7 US with results summarised in Table 5. Of the included studies, sixteen measured
8 echogenicity as a variable for structural change (Archambault, et al. 1998, Comin, et
9 al. 2013, Cook, et al. 2001, Cook, et al. 2000, Fredberg and Bolvig 2002, Fredberg,
10 et al. 2008, Giombini, et al. 2013, Gisslén and Alfredson 2005, Gisslén, et al. 2007,
11 Hirschmüller, et al. 2012, Jhingan, et al. 2011, Khan, et al. 1997, Khan, et al. 2003,
12 Malliaras, et al. 2010, Ooi, et al. 2015, Visnes, et al. 2015). Overall, abnormal
13 echogenicity was not defined in thirteen studies (Archambault, et al. 1998, Comin, et
14 al. 2013, Cook, et al. 2001, Cook, et al. 2000, Giombini, et al. 2013, Gisslén and
15 Alfredson 2005, Gisslén, et al. 2007, Hirschmüller, et al. 2012, Khan, et al. 1997,
16 Khan, et al. 2003, Malliaras, et al. 2010, Ooi, et al. 2015, Visnes, et al. 2015). Two
17 studies (Fredberg and Bolvig 2002, Jhingan, et al. 2011), defined abnormal
18 echogenicity as the presence of a hypoechoic region larger than 1mm in size, with
19 the remaining study (Fredberg, et al. 2008) using different values for the Achilles
20 tendon (0.5mm) and patellar tendon (1mm).

21

22 *Thickness*

23

24 All studies that measured echogenicity also measured tendon thickness
25 (Archambault, et al. 1998, Comin, et al. 2013, Cook, et al. 2001, Cook, et al. 2000,

1 Fredberg and Bolvig 2002, Fredberg, et al. 2008, Giombini, et al. 2013, Gisslén and
2 Alfredson 2005, Gisslén, et al. 2007, Hirschmüller, et al. 2012, Jhingan, et al. 2011,
3 Khan, et al. 1997, Khan, et al. 2003, Malliaras, et al. 2010, Ooi, et al. 2015, Visnes,
4 et al. 2015), with results presented in Table 6. Similarly, thirteen studies
5 (Archambault, et al. 1998, Comin, et al. 2013, Cook, et al. 2001, Cook, et al. 2000,
6 Giombini, et al. 2013, Gisslén and Alfredson 2005, Gisslén, et al. 2007, Hirschmüller,
7 et al. 2012, Khan, et al. 1997, Khan, et al. 2003, Malliaras, et al. 2010, Ooi, et al.
8 2015, Visnes, et al. 2015) determined the presence of increased thickness as
9 'abnormal', however, cut-off values were not defined. Two studies (Fredberg and
10 Bolvig 2002, Jhingan, et al. 2011) used a defined thickness as an increase of 1mm
11 when related to the normal distal part of the tendon, while one study (Fredberg, et al.
12 2008) classified tendon thickening >0.5mm in the Achilles tendon and thickening
13 >1mm in the patellar tendon as 'abnormal'.

14

15 *Vascularity*

16

17 Vascularity was measured in thirteen of the included studies (Boesen, et al.
18 2012, Comin, et al. 2013, de Jonge, et al. 2010, de Vos, et al. 2007, Giombini, et al.
19 2013, Gisslén and Alfredson 2005, Gisslén, et al. 2007, Hirschmüller, et al. 2012,
20 Jhingan, et al. 2011, Khan, et al. 2003, Malliaras, et al. 2010, Ooi, et al. 2015,
21 Visnes, et al. 2015). An outline of the criteria used to assess vascularity is provided
22 in Table 7. As outlined in Table 7, ten studies (Boesen, et al. 2012, de Jonge, et al.
23 2010, de Vos, et al. 2007, Giombini, et al. 2013, Gisslén and Alfredson 2005,
24 Gisslén, et al. 2007, Hirschmüller, et al. 2012, Malliaras, et al. 2010, Ooi, et al. 2015,
25 Visnes, et al. 2015) used varying scales to define 'abnormal' vascularity. The

1 remaining three studies (Comin, et al. 2013, Jhingan, et al. 2011, Khan, et al. 2003)
2 used the presence of vascularity, with undefined parameters, to determine whether a
3 tendon was classified as 'abnormal'.

4

5 *Meta-analysis*

6

7 Nine of the nineteen included studies were eligible for meta-analysis due to
8 similarities in characteristics (Cook, et al. 2001, Cook, et al. 2000, Giombini, et al.
9 2013, Gisslén and Alfredson 2005, Gisslén, et al. 2007, Jhingan, et al. 2011, Khan,
10 et al. 1997, Khan, et al. 2003, Ooi, et al. 2015). The remaining ten studies could not
11 be included due to insufficient data on the development of symptoms, significant
12 differences in study design and methodology, or the inclusion of symptomatic
13 tendons at baseline. Overall, Figure 2 demonstrates that tendon abnormalities on US
14 may be predictive of the development of future symptoms in both the patellar and
15 Achilles tendons (RR=4.78, 95% CI 2.49-9.15) with low heterogeneity between
16 studies ($I^2=0\%$).

17

18 *Predictive value of parameters*

19

20 Six studies (Giombini, et al. 2013, Gisslén and Alfredson 2005, Gisslén, et al.
21 2007, Jhingan, et al. 2011, Khan, et al. 2003, Ooi, et al. 2015) used three
22 parameters (echogenicity, thickness, vascularisation), while three studies (Cook, et
23 al. 2001, Cook, et al. 2000, Khan, et al. 1997) used two parameters (echogenicity
24 and thickness) when assessing structural change in patellar and Achilles tendons on
25 US. Three parameters were found to have an increased risk of developing symptoms

1 (RR=6.49, 95% CI 2.49-16.94) when compared to those studies using two
2 parameters (RR=3.66, 95% CI 1.15-11.62). I^2 values demonstrated low
3 heterogeneity across subgroups (3 parameters $I^2=7\%$, 2 parameters $I^2=6\%$). This
4 data is displayed in Figure 3.

5
6 In the patellar tendon, three studies (Giombini, et al. 2013, Gisslén and
7 Alfredson 2005, Gisslén, et al. 2007) used three parameters to assess structural
8 change, while three studies (Cook, et al. 2001, Cook, et al. 2000, Khan, et al. 1997)
9 assessed change using two parameters. Figure 4 demonstrates that three
10 parameters (RR=10.42, 95% CI 2.34-46.37) may indicate an increased risk of future
11 symptoms when compared to the use of two parameters (RR=3.03, 95% CI 1.15-
12 7.97). I^2 analysis showed low heterogeneity across both subgroups (3 parameters
13 $I^2=20\%$, 2 parameters $I^2=0\%$). All four studies (Giombini, et al. 2013, Jhingan, et al.
14 2011, Khan, et al. 2003, Ooi, et al. 2015) assessing the Achilles tendon used three
15 parameters and found an increased risk for developing symptoms (RR=5.45, 95% CI
16 1.62-18.37). Heterogeneity was low between the studies ($I^2=0\%$).

17
18 Statistical significance was found for the predictive value of US assessment of
19 the tendon matrix for both the Achilles ($p=0.006$) and patellar ($p=0.0001$) tendons.
20 There was no statistical difference between the two groups ($p=0.80$). Similarly, both
21 3 parameters ($p=0.0001$) and 2 parameters ($p=0.03$) were determined to be
22 statistically significant for predicting symptom development without a statistical
23 difference between the two groups ($p=0.45$). In the patellar tendon, there was a
24 statistical significance for the predictive value of both 3 parameters ($p=0.002$) and 2
25 parameters ($p=0.02$), with no statistical difference between groups ($p=0.17$). Funnel

1 plot analysis demonstrated no publication bias for all subgroup analysis (Figures 5, 6
2 and 7).

3

4 **Discussion**

5

6 There is considerable debate regarding the clinical utility of imaging in
7 tendinopathy (Docking, et al. 2015). There are two important issues to consider
8 which have led to this debate. The first issue is that in some studies abnormal
9 structural tendon changes, as seen with US, have been reported in up to 59% of
10 asymptomatic individuals (Brasseur, et al. 2004, Cook, et al. 1998, Fredberg and
11 Bolvig 2002, Giombini, et al. 2013, Hirschmüller, et al. 2012, Khan, et al. 1997,
12 Leung and Griffith 2008). It is therefore apparent that there is a disparity that can be
13 seen between the findings of imaging versus the clinical presentation (Fredberg, et
14 al. 2004). Secondly, although numerous studies have examined the sensitivity and
15 accuracy of imaging in identifying tendinopathy (Docking, et al. 2015, Scott, et al.
16 2013), there is a lack of a valid clinical gold standard for diagnosing tendinopathy
17 with which to reliably compare findings (Docking, et al. 2015). Additionally, with such
18 a wide variety of classification systems and different imaging features reported, there
19 appears to be a lack of agreement of an acceptable criterion or classification to
20 match structural changes seen on US with the clinical stages of tendinopathy (Ellis
21 and Manuel 2015). Furthermore, in the clinical setting, sonographers do not appear
22 to use or refer to the continuum model of tendinopathy when diagnosing tendon
23 disorders. Classifying patients according to structural changes, in addition to clinical
24 symptoms, may allow the clinician to direct treatment to the key limiting factors (pain,
25 function or load capacity) (Cook, et al. 2016, Scase, et al. 2011).

1

2 *Classification of tendinopathy*

3

4 The primary aim of this systematic review was to identify the current methods
5 used to classify tendinopathy using US. To the authors' knowledge, this is the first
6 systematic review and meta-analysis to focus specifically on current US parameters
7 used to measure structural change in tendinopathy and the methods of classifying
8 tendinopathy according to these parameters. We found that there is a distinct lack of
9 homogeneity in the criteria used when assessing tendinopathy using US. While there
10 is significant inconsistency in the currently used US tendinopathy classification
11 methods, common US parameters used to measure structural change can be
12 identified. These results align with those of Ellis and Manuel (Ellis and Manuel 2015),
13 which demonstrated significant variability in both the overall classification scales
14 used, and individual parameters measured from studies that examined tendinopathy
15 with US. Additionally, this review demonstrated that there is a lack of a relationship
16 between the classification systems employed clinically, and the widely accepted
17 continuum model (Cook and Purdam 2009) of tendinopathy.

18

19 *Quality of Included Studies*

20

21 One of the secondary aims of this literature review was to assess the
22 methodological quality of the literature. According to the previously described quality
23 scoring system and, as presented in Table 3, all included studies were determined to
24 be of good methodological quality. The main areas of concern within the
25 methodological quality of included studies was in the minimisation of bias (Comin, et

1 al. 2013, Jhingan, et al. 2011, Khan, et al. 2003, Malliaras, et al. 2010), control of
2 confounding factors (Archambault, et al. 1998, Comin, et al. 2013, Cook, et al. 2001,
3 de Vos, et al. 2007, Fredberg and Bolvig 2002, Gisslén and Alfredson 2005, Gisslén,
4 et al. 2007, Jhingan, et al. 2011, Khan, et al. 2003, Malliaras, et al. 2010), adequate
5 follow-up (Archambault, et al. 1998, Hirschmüller, et al. 2012) and the presentation
6 of results (Gisslén and Alfredson 2005, Gisslén, et al. 2007). Additionally, the main
7 weaknesses of the included randomised controlled trials were concerned with
8 recording of drop-outs (Fredberg, et al. 2008), blinding (de Jonge, et al. 2010,
9 Fredberg, et al. 2008), and the similarity of treatment and control groups (Fredberg,
10 et al. 2008). These results align with those of other systematic reviews (McAuliffe, et
11 al. 2016) and provide a methodologically sound base for future research.

12

13 *Predictive value of US based classification systems*

14

15 A secondary aim of this review was to assess the predictive value of different
16 US classification methods for the development of future symptoms. Overall, meta-
17 analysis demonstrated that US identified tendon abnormalities may present an
18 increased risk (RR=4.78) for the development of future symptoms in Achilles and
19 patellar tendinopathy. This aligns with the systematic review by McAuliffe et al.
20 (2016), who demonstrated US identified abnormalities were predictive (RR=4.97) for
21 the development of symptomatic lower limb tendinopathy. However, further sub-
22 group analysis according to parameters measured, showed significant differences to
23 the predictive value of US. Notably, when measuring tendon matrix changes using
24 US, the number of parameters measured may influence the predictive value of US in
25 asymptomatic patients.

1
2
3
4
5
6
7
8
9
10
11
12
13
14
15
16
17
18
19
20
21
22
23
24
25

Meta-analysis demonstrated that including three parameters (echogenicity, thickness and vascularity; RR=6.49) was more predictive than those using two parameters (echogenicity and thickness; RR=3.66) for the development of future symptoms in the lower limb. This was highlighted further when looking at the patellar tendon where RR was considerably higher when using three parameters (RR=10.49) compared to two parameters (RR=3.03). These results differ to those of McAuliffe et al. (2016) in that McAuliffe et al. (2016) demonstrated US identified abnormalities were a risk factor for the development of tendinopathy in both the Achilles and patella tendons. However, these results indicated that by utilising more parameters to define tendon abnormalities using US, the RR of developing future clinical tendinopathy may be increased. To the authors knowledge, this is the first research to investigate the impact of individual US parameters on the predictive value of tendinopathy.

The synthesis of evidence illustrates that there is still debate as to the predictive value of US, with 53% of included studies determining US findings were predictive of future symptoms. Hirschmüller et al. (2012) found that neovascularisation Grade 1 may be predictive (odds ratio(OR) 6.9, 95% CI 2.6-18.8, $p=0.0001$) of future symptoms, however, hypoechogenicity, spindle-shaped thickening, and neovascularisation Grade 2-3 were not predictive ($p>0.05$). Whereas, Comin et al. (2013) reported moderate to severe hypoechoic regions may be predictive of symptoms in both the patellar and Achilles tendons (Fisher's exact $p=0.038$). However, intratendon defects (patellar $p=0.166$, Achilles $p=0.403$) and neovascularisation (patellar $p=0.342$, Achilles 0.089) were not statistically significant

1 for predicting symptoms. Additionally, Boesen et al. (2012) found no association
2 between pain and abnormal neovascularisation at the end of a volleyball season with
3 35% of painful tendons demonstrating abnormal flow. Similarly, de Jonge et al.
4 (2010) demonstrated no significant difference in VISA-A scores between patients
5 with and without neovascularisation at baseline ($p=0.71$), while de Vos et al. (2007),
6 reported no statistical difference in the predictive value of neovascularisation when
7 compared to both the VAS ($p=0.053$) and VISA-A ($p=0.147$).

8

9 Conversely, Fredberg and Bolvig (2002) reported abnormal US had a 17%
10 risk of developing symptomatic jumper's knee and 45% risk of developing
11 symptomatic Achilles tendinopathy. Similarly, Fredberg et al. (2008) demonstrated
12 an abnormal US had a RR of 2.8 (95% CI, 1.6-4.9; $p=0.002$) in the Achilles tendon
13 and RR of 2.2 (95% CI, 0.9-5.7; $p=0.09$) for the patellar tendon. Additionally,
14 Malliaras et al. (2010) determined there was an increased probability of pain in
15 tendons with both hypoechoic regions (59%) and diffuse thickening (43%). This is
16 supported by Visnes et al. (2015) with both hypoechogenicity (OR 3.3, 95% CI 1.1-
17 9.2) and neovascularisation (OR 2.7, 95% CI 1.1-6.5) increasing the risk of
18 developing symptomatic jumper's knee.

19

20 This variability in the reported results may be explained by two important
21 factors. Firstly, research utilising US has been limited to classifying tendon structural
22 change with the use of subjective grading scores established on a multitude of
23 pathological features (Docking, et al. 2015, Ellis and Manuel 2015). Objective
24 measurement of tendon structural change, seen with US, has been restricted to
25 measuring dimensions such as tendon diameter, cross-sectional area of the tendon

1 and number or size of hypoechoic regions (Docking, et al. 2015). Secondly, although
2 numerous studies have examined the sensitivity and accuracy of US in identifying
3 tendinopathy (Docking, et al. 2015, Scott, et al. 2013), there is a lack of a valid
4 clinical gold standard for diagnosing tendinopathy, making assessing the clinical
5 utility of US difficult (Docking, et al. 2015, McAuliffe, et al. 2016).

6

7 *Limitations*

8

9 The exclusion of grey literature may increase the risk of publication bias
10 (Conn, et al. 2003). It is also possible that non-English articles that may have met the
11 inclusion criteria were missed. However, there is no evidence of systematic review
12 bias from language restrictions (Morrison, et al. 2012). The exclusion of promising
13 methods of US, such as elastography, may have an effect on publication bias.
14 However, although early research shows promise as an adjunct to standard US (Ooi,
15 et al. 2014), evidence is limited to smaller cross-sectional studies and there are
16 some technical challenges to producing high-quality, reproducible elastograms
17 (Domenichini, et al. 2017, Ooi, et al. 2014, Ryu and Jeong 2017). Moreover, as
18 elastography is a recent development, many commercial US units lack the ability to
19 assess this feature. A better understanding of fundamental properties of
20 elastography (Ryu and Jeong 2017) and standardisation of imaging protocols (Ooi,
21 et al. 2014) may allow future research to incorporate this technique into the US
22 assessment of tendon matrix change. Additionally, study quality was assessed using
23 the CASP tool (Critical Appraisal Skills Programme 2017, Critical Appraisal Skills
24 Programme 2017), which does not utilise a scoring system to grade study quality,
25 thus one was developed for the purpose of the review. The selection of quality

1 appraisal tool may impact review conclusions (Voss and Rehfuess 2013), however,
2 this was addressed by using two independent reviewers and determining inter-rater
3 agreement for each question on the checklist.

4

5 *Implications for future research*

6

7 Given the complexity of the relationship between structure, dysfunction and
8 pain in tendinopathy, there is scope to develop a standardised method to assess
9 tendon structural change on US, incorporating a number of parameters, and allowing
10 for greater consistency in the diagnosis of tendinopathy. Based on the results of this
11 systematic review and meta-analysis, future criteria for diagnosing tendinopathy
12 using US should include measures of all three parameters (tendon thickness,
13 echogenicity and vascularity) when assessing tendon structural change.

14 Furthermore, there is a need for further studies to assess the validity of developing a
15 clinical gold standard for the diagnosis of tendinopathy that incorporates both clinical
16 and US findings to formulate a diagnosis of tendinopathy. Additionally, in order to
17 better integrate clinical and US findings, there is an opportunity to develop a method
18 that merges the continuum model with US parameters to form an overall criteria that
19 allows for greater consistency in the diagnosis of tendinopathy. Using the results of
20 this literature review, an ordinal scale may be developed to diagnose tendinopathy
21 using US as 'normal', 'reactive/early dysrepair' or 'late dysrepair/degenerative' to
22 better align with the continuum model (Ellis and Manuel, 2015, Scase, et al. 2011).

23 However, cut-off values would need to be determined to distinguish between the
24 different stages within the continuum.

25

1 *Conclusions*

2

3 This review demonstrates that there is significant variability in the US based
4 criteria used to diagnose tendinopathy. Notably, US is predictive of the development
5 of future clinical symptoms. Furthermore, the assessment of tendon structural
6 change using three parameters revealed a higher RR when compared to using two
7 parameters, indicating the predictive value of using three parameters. Furthermore,
8 as imaging is one component of the clinical picture, there is scope to for future
9 research to develop a standardised criterion that incorporates both clinical and US
10 features to diagnose tendinopathy. This has the potential to improve the monitoring
11 and clinical management of tendinopathies.

Table 1: Search strategy used for database search

Database	Search Strategy
ProQuest	((mesh(tendinopathy) OR all(tendinopath* OR tendonopath* OR tendinitis OR tendinosis)) AND ((mesh(ultrasonography) OR all(ultrasonograph* OR ultrasound OR sonograph*)) AND all(classification OR classify* OR grade OR grading OR stage OR staging OR characteris* OR characteriz*))
PubMed	((("Tendinopathy"[Mesh]) AND (tendinopath* OR tendonopath* OR tendinitis OR tendinosis)) AND ("Ultrasonography"[Mesh]) AND (ultrasonograph* OR ultrasound OR sonograph*)) AND (classification OR classify* OR grade OR grading OR stage OR staging OR characteris* OR characteriz*)
Embase	('tendinitis'/exp OR tendinopath* OR tendonopath* OR tendinitis OR tendinosis) AND ('echography'/exp OR ultrasonograph* OR ultrasound OR sonograph*) AND classification OR classify* OR grade OR grading OR stage OR staging OR characteris* OR characteriz*
CINAHL	(MH "Tendinopathy+" OR tendinopath* OR tendonopath* OR tendinitis OR tendinosis) AND (MH "Ultrasonography+" OR ultrasonograph* OR ultrasound OR sonograph*) AND classification OR classify* OR grade OR grading OR stage OR staging OR characteris* OR characteriz*
SPORTDiscus	(DE "TENDINITIS" OR DE "ACHILLES tendinitis" OR DE "CALCIFIC tendinitis" OR tendinopath* OR tendonopath* OR tendinitis OR tendinosis) AND (DE "ULTRASONIC imaging" OR DE "DIAGNOSTIC ultrasonic imaging" OR ultrasonograph* OR ultrasound OR sonograph*) AND (classification OR classify* OR grade OR grading OR stage OR staging OR characteris* OR characteriz*)

Table 2: Characteristics of included studies

Author	Study Design	Demographics	Population	Tendon	US Structural Changes	Classification	Ultrasound Imaging & Follow Up
Archambault, et al. (1998)	Cohort Study	N = 33 (M - 20, F - 13) Mean Age - 35.8 (range 18-59)	Sports Medicine Clinic	Achilles	Echogenicity Thickness	1: Normal (parallel margins, homogeneous) 2: Enlarged tendon (bowed margins, homogeneous) 3: Hypoechoic (with or without enlargement)	US: Initial visit Follow Up: 24.3 months
Boesen, et al. (2012)	Cohort Study	N = 86 (M - 56, F - 30) Mean Age - 21.7 (range N/A)	Badminton	Achilles Patellar Quadriceps	Vascularity	0: no Doppler 1: 1 or 2 tiny foci 2: <5% colour ROI 3: 5-24% colour ROI 4: 25-49% colour ROI 5: >50% colour ROI	US: Initial & Follow Up Follow-up: 8 months
Comin, et al. (2013)	Cohort Study	N = 79 (M - 35, F - 44) Mean Age - 27.6 (range 18-40)	Ballet Dancers	Achilles Patellar	Echogenicity Thickness Vascularity Calcification	Normal Abnormal: presence of (1) hypoechoogenicity (undefined), or (2) incr. thickness (undefined), or (3) vascularity (undefined), or (4) intratendon calcification (undefined)	US: Initial visit Follow Up: 24 months
Cook, et al. (2000)	Cohort Study	N = 26 (M - 8, F - 18) Mean Age - N/A (range 14-18)	Junior Basketball	Patellar	Echogenicity Thickness	Normal Abnormal: presence of (1) hypoechoic region, or (2) fusiform swelling (all undefined)	US: Initial & Follow Up Follow Up: 16 months (12-24 months)
Cook, et al. (2001)	Cohort Study	N = 24 (M -24) Mean Age - 29.8 (at follow-up)	Football, Basketball, Cricket	Patellar	Echogenicity Thickness	Normal Abnormal: presence of (1) hypoechoic region, or (2) fusiform swelling (all undefined)	US: Initial & Follow Up Follow Up: 47.1 months (32-80 months)

de Jonge, et al. (2010)	RCT	N = 50 (63 tendons - M - 26, F -37) Mean Age - 44.6 (range 26-59)	Sports Medicine Clinic	Achilles	Vascularity	0: no vessels 1: one vessel mostly in anterior part 2: one/two vessels throughout tendon 3: three vessels throughout tendon 4: >3 large vessels throughout tendon	US: Initial & Follow Up Follow Up: 12 months
de Vos, et al. (2007)	Cohort Study	N = 52 (63 tendons - M - 26, F -37) Mean Age - 44.6 (range 26-59)	Sports Medicine Clinic	Achilles	Vascularity	0: no vessels 1+: one vessel mostly in anterior part 2+: one/two vessels throughout tendon 3+: three vessels throughout tendon 4+: >3 large vessels throughout tendon	US: Initial & Follow Up Follow Up: 12 weeks
Fredberg and Bolvig (2002)	Cohort Study	N = 54 (M - 54) Mean Age - N/A (range 18-35)	Soccer	Achilles Patellar	Echogenicity Thickness	Normal Abnormal: presence of (1) >1mm thickening (2) > 1mm hypoechoic region	US: Initial & Follow Up Follow Up: 12 months
Fredberg, et al. (2008)	RCT	N = 207 (M - 207) Mean Age - 25.0 (range 17-37)	Soccer	Achilles Patellar	Echogenicity Thickness	Normal Slightly Abnormal: (1) Thickening 0.5-1mm (2) Hypoechoic region 1-2mm Severely Abnormal: (1) Thickening >1mm (2) Hypoechoic region >2mm	US: Initial & Follow Up Follow Up: 12 months
Giombini, et al. (2013)	Cohort Study	N = 37 (M - 15, F - 22) Mean Age - 27 (range 16-36)	Fencers	Achilles Patellar Quadriceps	Echogenicity Thickness Vascularity	Normal Abnormal: presence of (1) Focal/Diffuse thickening (undefined) (2) Focal/Diffuse hypoechogenicity (undefined) (3) Vascularity >2 (0- no flow, 1- flow outside tendon, 2- 1 or 2 vessels inside tendon, 3- multiple vessels inside tendon)	US: Initial & Follow Up Follow Up: Avg. 3 years

Gisslén and Alfredson (2005)	Cohort Study	N = 60 (M - 29, F - 31) Mean Age - 17.2 (range 15-19)	Junior Volleyball	Patellar	Echogenicity Thickness Vascularity	Normal Abnormal: presence of (1) Increased thickness (undefined) (2) Hypoechoogenicity (undefined) (3) Vascularity >2 (0- no flow, 1- flow outside tendon, 2- 1 or 2 vessels inside tendon, 3- multiple vessels inside tendon)	US: Initial & Follow Up Follow Up: 7 months
Gisslén, et al. (2007)	Cohort Study	N = 22 (M - 11, F - 11) Mean Age - 16.3 (range 15-16 at start)	Junior Volleyball	Patellar	Echogenicity Thickness Vascularity	Normal Abnormal: presence of (1) Increased thickness (undefined) (2) Hypoechoogenicity (undefined) (3) Vascularity >2 (0- no flow, 1- flow outside tendon, 2- 1 or 2 vessels inside tendon, 3- multiple vessels inside tendon)	US: Initial, Regular intervals & Follow Up (6 total) Follow Up: 3 years
Hirschmüller, et al. (2012)	Cohort Study	N = 634 (M - 425, F - 209) Mean Age - 41.2 (range 17-73)	Long Distance Runners	Achilles	Echogenicity Thickness Vascularity	Normal Abnormal: presence of (1) Tendon thickening (undefined) (2) Hypo/hyper echogenicity (undefined) (3) Vascularity (0 – no Doppler, 1 – 1 or 2 tiny foci, 2 – <5% colour ROI, 3 – 5-24% colour ROI, 4 – 25-49% colour ROI, 5 – 50% colour ROI)	US: Initial visit Follow Up: 12 months
Jhingan, et al. (2011)	Cohort Study	N = 18 (M -18) Mean Age - 23.5 (range 22-27.5)	Soccer	Achilles	Echogenicity Thickness Vascularity	Normal Abnormal: presence of (1) Thickening (> 1mm) (2) Hypoechoogenicity (> 1mm) (3) Paratendon Blurring (4) Vascularity (undefined)	US: Initial visit Follow Up: 12 months
Khan, et al. (1997)	Cohort Study	N = 30 (F - 30) Mean Age – 24 (range N/A)	Basketball	Patellar	Echogenicity Thickness	Normal Abnormal: presence of (1) Increased thickness (undefined) (2) Hypoechoogenicity (undefined)	US: Initial & Follow Up Follow Up: 18.3 months (range 12-34 months)

Khan, et al. (2003)	Cohort Study	N = 45 (M - 27, F - 18) Mean Age - 42 (range 20-66)	Sports Medicine Centre	Achilles	Echogenicity Thickness Vascularity	1: Normal 2: Thickened (>6mm) homogenous echotexture 3: Hypo/Hyperechoic areas with/without thickening (>6mm) Vascularity: normal or abnormal	US: Initial & 12 months Follow Up: 24 months
Malliaras, et al. (2010)	Cohort Study	N = 58 (M -36, F - 22) Mean Age - 37.3 (range N/A)	Volleyball	Patellar	Echogenicity Thickness Vascularity	Normal Abnormal: presence of Diffuse Thickening (undefined) Hypoechogenicity (undefined) Vascularity min 1 vessel >1mm in length in sagittal plane	US: Initial & Monthly Follow Up: 5 months
Ooi, et al. (2015)	Cohort Study	N = 41 (M - 25, F- 16) Mean Age - 37.3 (range N/A)	Runners	Achilles	Echogenicity Thickness Vascularity	1: Normal 2: heterogeneous echotexture (undefined), bowed tendon margins (undefined), mild neovascularisation (1 or 2 intratendinous vessels >1mm in length) 3: marked thickening (undefined), discrete hypoechoic areas (undefined), moderate to severe neovascularisation (>2 vessels peripheral and internal)	US: Initial (Pre-race 1wk) & 3-days post-race Follow Up: 10 days
Visnes, et al. (2015)	Cohort Study	N = 158 (M - 74, F - 84) Mean Age - 16.8 (range N/A)	Junior Volleyball	Patellar Quadriceps	Echogenicity Thickness Vascularity	Normal Abnormal: presence of (1) hypoechogenicity (undefined) or (2) thickness (undefined) (3) increased vascularity > stage 2 (0- no flow, 1- flow outside tendon, 2- 1 or 2 vessels inside tendon, 3- multiple vessels inside tendon)	US: Initial & 6-monthly Follow Up 4 years (average 1.7years)

Notes: N = number, M = male, F = female, US = ultrasound imaging, N/A = not available, incr. = increased, RCT = randomised controlled trial, mm = millimetres, wk = week

Table 3: Summary of CASP scores for included studies

	Cohort Studies												Score
	1	2	3	4	5a	5b	6a	6b	7	10	11	12	
Archambault, et al. (1998)	✓	✓	✓	✓	✓	X	X	X	✓	✓	✓	✓	75%
Boesen, et al. (2012)	✓	✓	✓	✓	✓	✓	✓	✓	✓	✓	✓	✓	100%
Comin, et al. (2013)	✓	✓	X	✓	X	X	✓	✓	✓	✓	✓	✓	75%
Cook, et al. (2000)	✓	✓	✓	✓	✓	✓	✓	✓	✓	✓	✓	✓	100%
Cook, et al. (2001)	✓	✓	✓	✓	✓	X	✓	✓	✓	✓	✓	✓	92%
de Vos, et al. (2007)	✓	✓	✓	✓	X	X	✓	✓	✓	✓	✓	✓	83%
Fredberg and Bolvig (2002)	✓	✓	✓	✓	X	X	✓	✓	✓	✓	✓	✓	83%
Giombini, et al. (2013)	✓	✓	✓	✓	✓	✓	✓	✓	✓	✓	✓	✓	100%
Gisslén and Alfredson (2005)	✓	✓	✓	✓	✓	X	✓	✓	X	✓	✓	✓	83%
Gisslén, et al. (2007)	✓	✓	✓	✓	✓	X	✓	✓	X	✓	✓	✓	83%
Hirschmüller, et al. (2012)	✓	✓	✓	✓	✓	✓	X	X	✓	✓	✓	✓	83%
Jhingan, et al. (2011)	✓	✓	X	✓	X	X	✓	✓	✓	✓	✓	✓	75%
Khan, et al. (1997)	✓	✓	✓	✓	✓	✓	✓	✓	✓	✓	✓	✓	100%
Khan, et al. (2003)	✓	✓	X	✓	X	X	✓	✓	✓	✓	✓	✓	75%
Malliaras, et al. (2010)	✓	✓	X	✓	X	X	✓	✓	✓	✓	✓	✓	75%
Ooi, et al. (2015)	✓	✓	✓	✓	✓	✓	✓	✓	✓	✓	✓	✓	100%
Visnes, et al. (2015)	✓	✓	✓	✓	✓	✓	✓	✓	✓	✓	✓	✓	100%
	Randomised Controlled Trials												
	1	2	3	4	5	6	7	9	10	11			
de Jonge, et al. (2010)	✓	✓	✓	X	✓	✓	✓	✓	✓	✓	90%		
Fredberg, et al. (2008)	✓	✓	X	X	X	X	✓	✓	✓	✓	60%		

Notes: CASP = Critical Appraisal Skills Programme, ✓ = yes, X = no

Table 4: Synthesis of Evidence

Author	US Parameter Assessed				Study Quality	Was the criteria able to predict outcomes?	Is the criteria based off the continuum model?
	Echogenicity	Thickness	Vascularisation	Fibrillar Pattern			
Archambault, et al. (1998)	✓	✓	✗	✗	Good	✓	✗
Boesen, et al. (2012)	✗	✗	✓	✗	Good	✗	✗
Comin, et al. (2013)	✓	✓	✓	✗	Good	✗	✗
Cook, et al. (2000)	✓	✓	✗	✗	Good	✓	✗
Cook, et al. (2001)	✓	✓	✗	✗	Good	✗	✗
de Jonge, et al. (2010)	✗	✗	✓	✗	Good	✗	✗
de Vos, et al. (2007)	✗	✗	✓	✗	Good	✗	✗
Fredberg and Bolvig (2002)	✓	✓	✗	✗	Good	✓	✗
Fredberg, et al. (2008)	✓	✓	✗	✗	Good	✓	✗
Giombini, et al. (2013)	✓	✓	✓	✗	Good	✓	✗
Gisslén and Alfredson (2005)	✓	✓	✓	✗	Good	✓	✗
Gisslén, et al. (2007)	✓	✓	✓	✗	Good	✓	✗
Hirschmüller, et al. (2012)	✓	✓	✓	✗	Good	✗	✗
Jhingan, et al. (2011)	✓	✓	✓	✗	Good	✗	✗
Khan, et al. (1997)	✓	✓	✗	✗	Good	✓	✗
Khan, et al. (2003)	✓	✓	✓	✗	Good	✗	✗
Malliaras, et al. (2010)	✓	✓	✓	✗	Good	✓	✗
Ooi, et al. (2015)	✓	✓	✓	✗	Good	✗	✗
Visnes, et al. (2015)	✓	✓	✓	✗	Good	✓	✗

Notes: US = ultrasound imaging, ✓ = yes, ✗ = no

Table 5: Classification of Echogenicity

Author	Grading/Classification	Abnormal Echogenicity
Nominal Scale		
Comin, et al. (2013)	Normal Abnormal: presence of [1] hypoechogenicity, or [2] increased thickness, or [3] vascularity, or [4] intratendon defect (all undefined)	Presence of hypoechoic regions (undefined)
Cook, et al. (2000)	Normal Abnormal: presence of [1] hypoechoic region, or [2] fusiform swelling (both undefined)	Presence of hypoechoic regions (undefined)
Cook, et al. (2001)	Normal Abnormal: presence of [1] hypoechoic region, or [2] fusiform swelling (both undefined)	Presence of hypoechoic regions (undefined)
Fredberg and Bolvig (2002)	Normal Abnormal: presence of [1] thickening >1mm, or [2] hypoechoic region >1mm	Hypoechoic region >1mm
Giombini, et al. (2013)	Normal Abnormal: presence of [1] focal/diffuse thickening, or [2] focal/diffuse hypoechogenicity, or [3] vascularity > grade 2	Focal/Diffuse hypoechogenicity (undefined)
Gisslén and Alfredson (2005)	Normal Abnormal: presence of [1] increased thickness, or [2] hypoechogenicity, or [3] vascularity > grade 2	Presence of hypoechoic regions (undefined)
Gisslén, et al. (2007)	Normal Abnormal: presence of [1] increased thickness, or [2] hypoechogenicity, or [3] vascularity > grade 2	Presence of hypoechoic regions (undefined)

Hirschmüller, et al. (2012)	Normal Abnormal: presence of [1] increased thickness, or [2] hypo/hyper echogenicity, or [3] vascularity > grade 1	Presence of hyper/hypo echoic regions (undefined)
Jhingan, et al. (2011)	Normal Abnormal: presence of [1] thickening >1mm, or [2] hypoechogenicity >1mm, or [3] paratendon blurring, or [4] vascularity	Hypoechoic region >1mm
Khan, et al. (1997)	Normal Abnormal: presence of [1] increased thickness, or [2] hypoechogenicity (both undefined)	Presence of hypoechoic regions (undefined)
Malliaras, et al. (2010)	Normal Abnormal: presence of [1] diffuse thickening, or [2] hypoechogenicity (both undefined), or [3] vascularity >1mm	Presence of hypoechoic regions (undefined)
Visnes, et al. (2015)	Normal Abnormal: presence of [1] increased thickness, or [2] hypoechogenicity, or [3] vascularity > grade 2	Presence of hypoechoic regions (undefined)

Ordinal Scale

Archambault, et al. (1998)	Grade 1: Normal (parallel margins, homogeneous) Grade 2: Enlarged tendon (bowed margins, homogeneous) Grade 3: Hypoechoic (with or without enlargement)	Grade 3: Presence of hypoechoic regions (undefined)
Fredberg, et al. (2008)	Normal Slightly Abnormal: presence of [1] thickening or hypoechoic region 0.5-1mm in AT, and [2] thickening or hypoechoic region 1-2mm in PT Severely Abnormal: presence of [1] thickening or hypoechoic region >1mm AT, and thickening or hypoechoic region >2mm in PT	Hypoechoic region >0.5mm in AT Hypoechoic region >1mm in PT

Khan, et al. (2003)

Grade 1: Normal

Grade 2: Thickened (>6mm), homogenous echotexture

Grade 3: Hyper/hypo echoic areas with/without thickening

Vascularity: normal or abnormal

Grade 3: Presence of hyper/hypo echoic regions (undefined)

Ooi, et al. (2015)

Grade 1: Normal

Grade 2: Heterogeneous echotexture, bowed tendon margins, mild neovascularisation

Grade 3: discrete hypoechoic areas, marked thickening, moderate to severe neovascularisation

Grades 2-3: heterogeneous echotexture (undefined) or discrete hypoechoic regions (undefined)

Notes: mm = millimetres, AT = Achilles tendon, PT = patellar tendon

Table 6: Classification of Tendon Thickness

Author	Grading/Classification	Abnormal Thickness
Nominal Scales		
Comin, et al. (2013)	<p>Normal Abnormal: presence of [1] hypoechogenicity, or [2] increased thickness, or [3] vascularity, or [4] intratendon defect (all undefined)</p>	Increased thickness (undefined)
Cook, et al. (2000)	<p>Normal Abnormal: presence of [1] hypoechoic region, or [2] fusiform swelling (both undefined)</p>	Fusiform swelling (undefined)
Cook, et al. (2001)	<p>Normal Abnormal: presence of [1] hypoechoic region, or [2] fusiform swelling (both undefined)</p>	Fusiform swelling (undefined)
Fredberg and Bolvig (2002)	<p>Normal Abnormal: presence of [1] thickening >1mm, or [2] hypoechoic region >1mm</p>	Thickening >1mm
Giombini, et al. (2013)	<p>Normal Abnormal: presence of [1] focal/diffuse thickening, or [2] focal/diffuse hypoechogenicity, or [3] vascularity > grade 2</p>	Focal/Diffuse thickening (undefined)
Gisslén and Alfredson (2005)	<p>Normal Abnormal: presence of [1] increased thickness, or [2] hypoechogenicity, or [3] vascularity > grade 2</p>	Increased thickness (undefined)
Gisslén, et al. (2007)	<p>Normal Abnormal: presence of [1] increased thickness, or [2] hypoechogenicity, or [3] vascularity > grade 2</p>	Increased thickness (undefined)

Hirschmüller, et al. (2012)	Normal Abnormal: presence of [1] increased thickness, or [2] hypo/hyper echogenicity, or [3] vascularity > grade 1	Increased thickness (undefined)
Jhingan, et al. (2011)	Normal Abnormal: presence of [1] thickening >1mm, or [2] hypoechogenicity >1mm, or [3] paratendon blurring, or [4] vascularity	Thickening >1mm
Khan, et al. (1997)	Normal Abnormal: presence of [1] increased thickness, or [2] hypoechogenicity (both undefined)	Increased thickness (undefined)
Malliaras, et al. (2010)	Normal Abnormal: presence of [1] diffuse thickening, or [2] hypoechogenicity (both undefined), or [3] vascularity >1mm	Increased thickness (undefined)
Visnes, et al. (2015)	Normal Abnormal: presence of [1] increased thickness, or [2] hypoechogenicity, or [3] vascularity > grade 2	Increased thickness (undefined)

Ordinal Scales

Archambault, et al. (1998)	Grade 1: Normal (parallel margins, homogeneous) Grade 2: Enlarged tendon (bowed margins, homogeneous) Grade 3: Hypoechoic (with or without enlargement)	Grade 2-3: Enlarged tendon with bowed margins (undefined)
Fredberg, et al. (2008)	Normal Slightly Abnormal: presence of [1] thickening or hypoechoic region 0.5-1mm in AT, and [2] thickening or hypoechoic region 1-2mm in PT Severely Abnormal: presence of [1] thickening or hypoechoic region >1mm AT, and thickening or hypoechoic region >2mm in PT	Thickening >0.5mm in AT Thickening >1mm in PT

Khan, et al. (2003)	<p>Grade 1: Normal</p> <p>Grade 2: Thickened (>6mm), homogenous echotexture</p> <p>Grade 3: Hyper/hypo echoic areas with/without thickening</p> <p>Vascularity: normal or abnormal</p>	Tendon diameter >6mm
Ooi, et al. (2015)	<p>Grade 1: Normal</p> <p>Grade 2: Heterogeneous echotexture, bowed tendon margins, mild neovascularisation</p> <p>Grade 3: discrete hypoechoic areas, marked thickening, moderate to severe neovascularisation</p>	Grade 2-3: Increased thickness (undefined)

Notes: mm = millimetres, AT = Achilles tendon, PT = patellar tendon

Table 7: Classification of Vascularity

Author	Grading/Classification	Abnormal Vascularity
Nominal Scales		
Comin, et al. (2013)	<p>Normal Abnormal: presence of [1] hypoechogenicity, or [2] increased thickness, or [3] vascularity, or [4] intratendon defect (all undefined)</p>	Presence of vascularity (undefined)
Giombini, et al. (2013)	<p>Normal Abnormal: presence of [1] focal/diffuse thickening, or [2] focal/diffuse hypoechogenicity, or [3] vascularity >2 (0- no flow, 1- flow outside tendon, 2- 1 or 2 vessels inside tendon, 3- multiple vessels inside tendon)</p>	Vascularity Grade 2-3: >1 vessel inside tendon
Gisslén and Alfredson (2005)	<p>Normal Abnormal: presence of [1] increased thickness, or [2] hypoechogenicity, or [3] vascularity >2 (0- no flow, 1- flow outside tendon, 2- 1 or 2 vessels inside tendon, 3- multiple vessels inside tendon)</p>	Vascularity Grade 2-3: >1 vessel inside tendon
Gisslén, et al. (2007)	<p>Normal Abnormal: presence of [1] increased thickness, or [2] hypoechogenicity, or [3] vascularity >2 (0- no flow, 1- flow outside tendon, 2- 1 or 2 vessels inside tendon, 3- multiple vessels inside tendon)</p>	Vascularity Grade 2-3: >1 vessel inside tendon
Hirschmüller, et al. (2012)	<p>Normal Abnormal: presence of [1] increased thickness, or [2] hypo/hyper echogenicity, or [3] vascularity >1 (0 – no Doppler, 1 – 1 or 2 tiny foci, 2 – <5% colour ROI, 3 – 5-24% colour ROI, 4 – 25-49% colour ROI, 5 – >50% colour ROI)</p>	Vascularity Grade 1-5: >1 or 2 tiny foci

Jhingan, et al. (2011)	Normal Abnormal: presence of [1] thickening >1mm, or [2] hypoechogenicity >1mm, or [3] paratendon blurring, or [4] vascularity	Presence of vascularity (undefined)
Malliaras, et al. (2010)	Normal Abnormal: presence of [1] diffuse thickening, or [2] hypoechogenicity (both undefined), or [3] vascularity >1mm	Presence of >1 vessel >1mm in length
Visnes, et al. (2015)	Normal Abnormal: presence of [1] increased thickness, or [2] hypoechogenicity, or [3] vascularity >2(0 - no flow, 1 - flow outside tendon, 2 - 1 or 2 vessels inside tendon, 3 - multiple vessels inside tendon)	Vascularity Grade 2-3: >1 vessel inside tendon

Ordinal Scales

Boesen, et al. (2012)	0 – no Doppler 1 – 1 or 2 tiny foci 2 – <5% colour ROI 3 – 5-24% colour ROI 4 – 25-49% colour ROI 5 – >50% colour ROI	Grade 2-5: > 1 or 2 tiny foci
de Jonge, et al. (2010)	0 – no vessels 1 – one vessel mostly in anterior part 2 – one/two vessels throughout tendon 3 – three vessels throughout tendon 4 – >3 large tendons throughout tendon	Grade 1-4: > 1 vessel in tendon
de Vos, et al. (2007)	0 – no vessels 1+ – one vessel mostly in anterior part 2+ – one/two vessels throughout tendon 3+ – three vessels throughout tendon 4+ – >3 large vessels throughout tendon	Grade 1-4: >1 vessel in tendon

Khan, et al. (2003)	<p>Grade 1: Normal</p> <p>Grade 2: Thickened (>6mm), homogenous echotexture</p> <p>Grade 3: Hyper/hypo echoic areas with/without thickening</p> <p>Vascularity: normal or abnormal</p>	Presence of vascularity (undefined)
Ooi, et al. (2015)	<p>Grade 1: Normal</p> <p>Grade 2: Heterogeneous echotexture, bowed tendon margins, mild neovascularisation (1 or 2 intratendinous vessels >1mm in length)</p> <p>Grade 3: discrete hypoechoic areas, marked thickening, moderate to severe neovascularisation (>2 vessels peripheral and internal)</p>	Grade 2-3: >1 vessel >1mm in length

Notes: ROI = region of interest, mm = millimetre

Figure 1

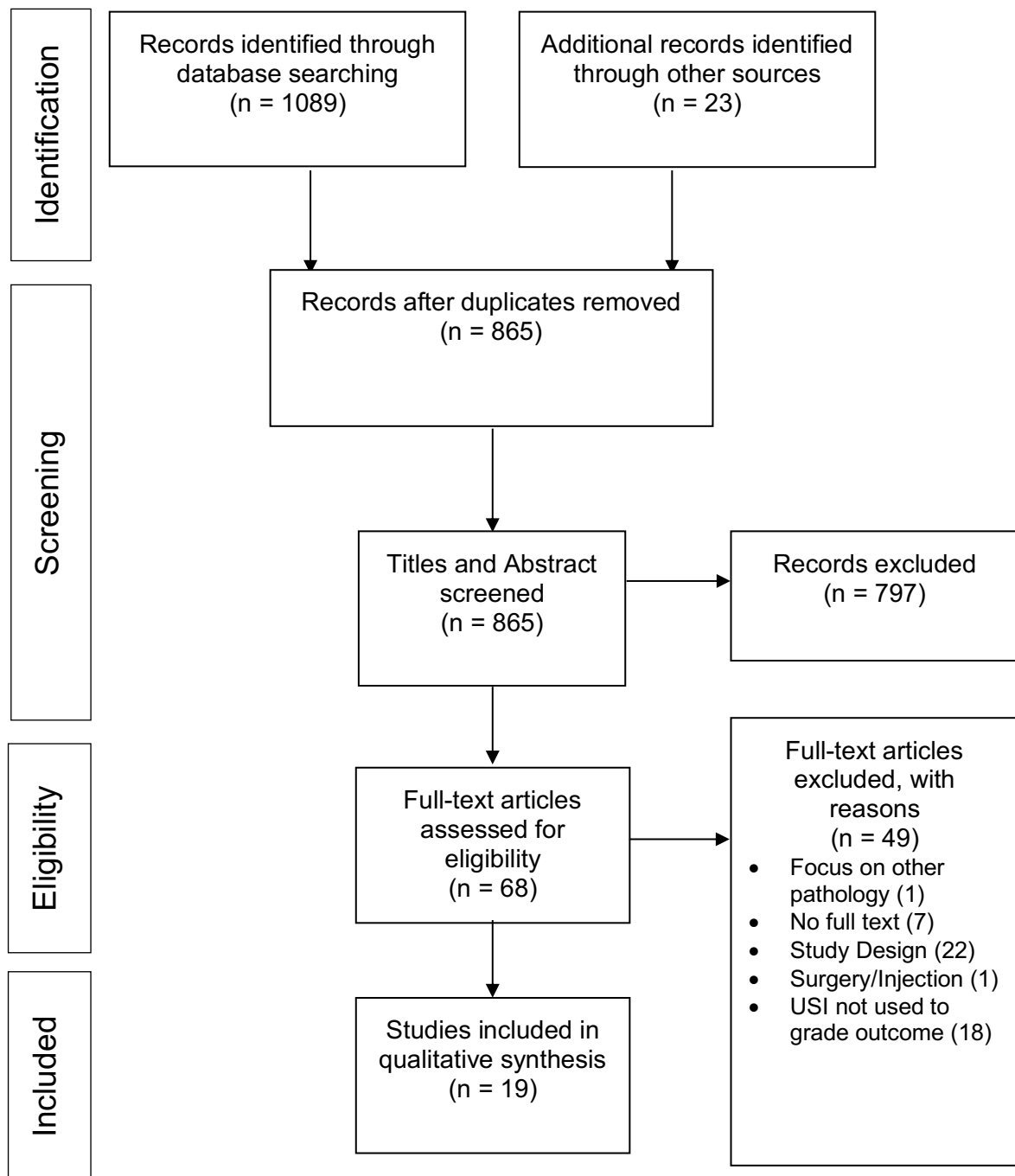


Figure 2

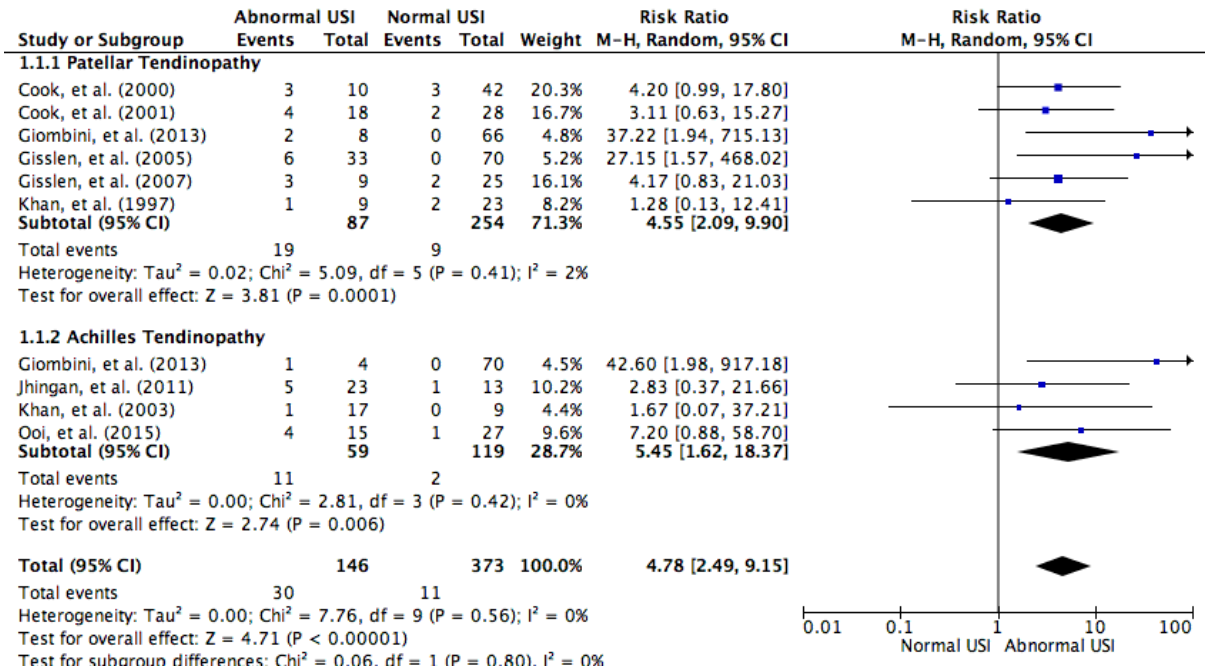


Figure 3

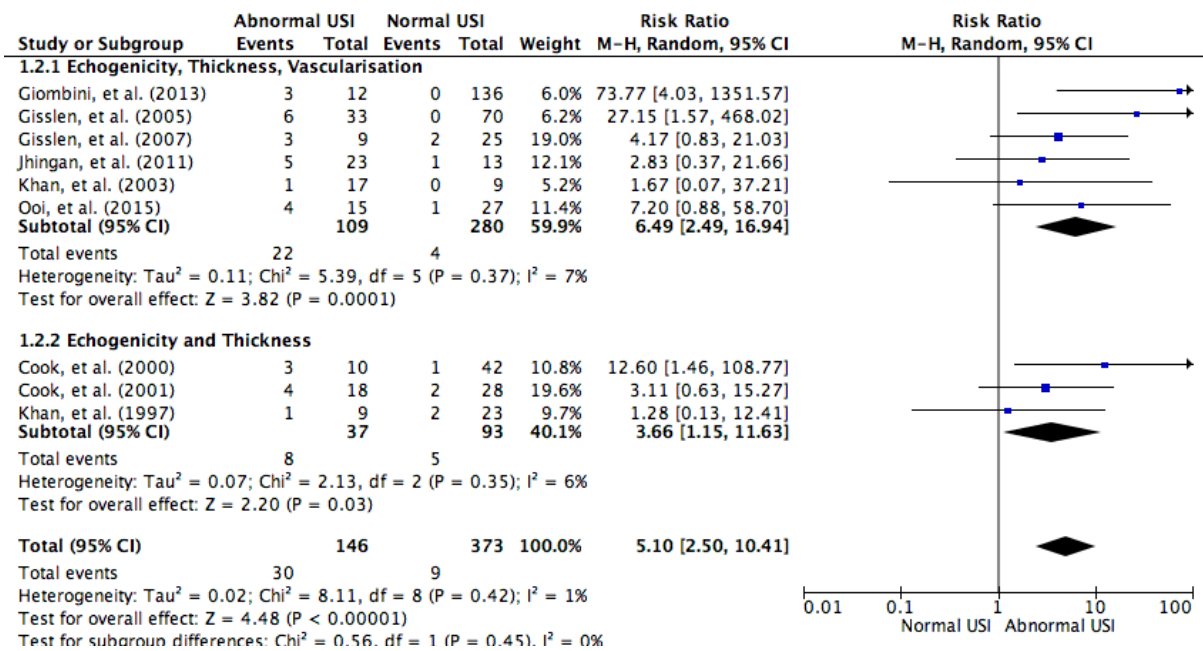


Figure 4

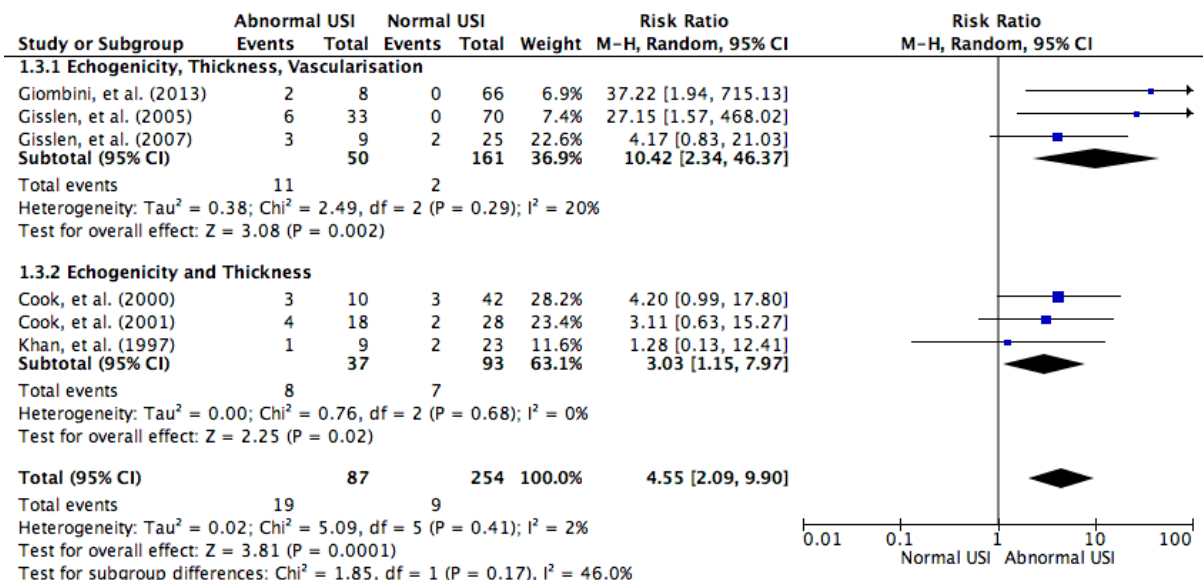


Figure 5

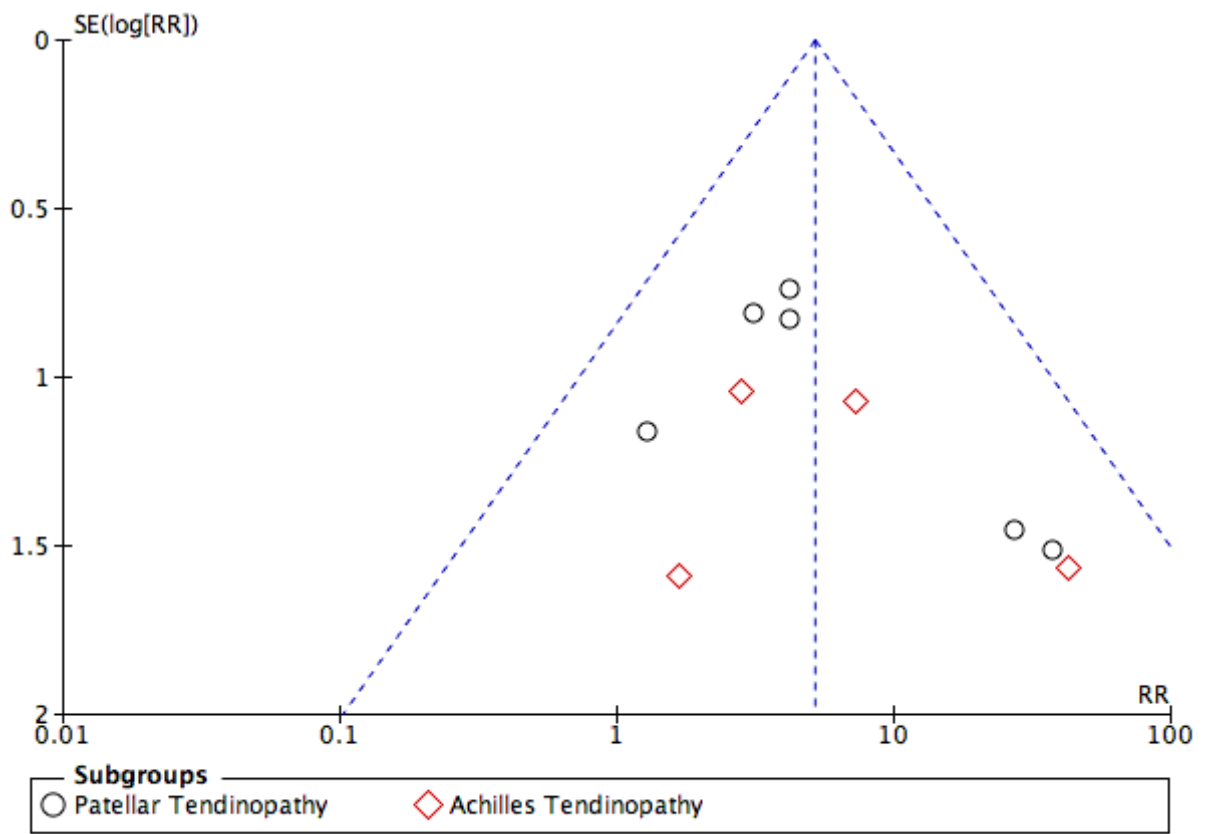


Figure 6

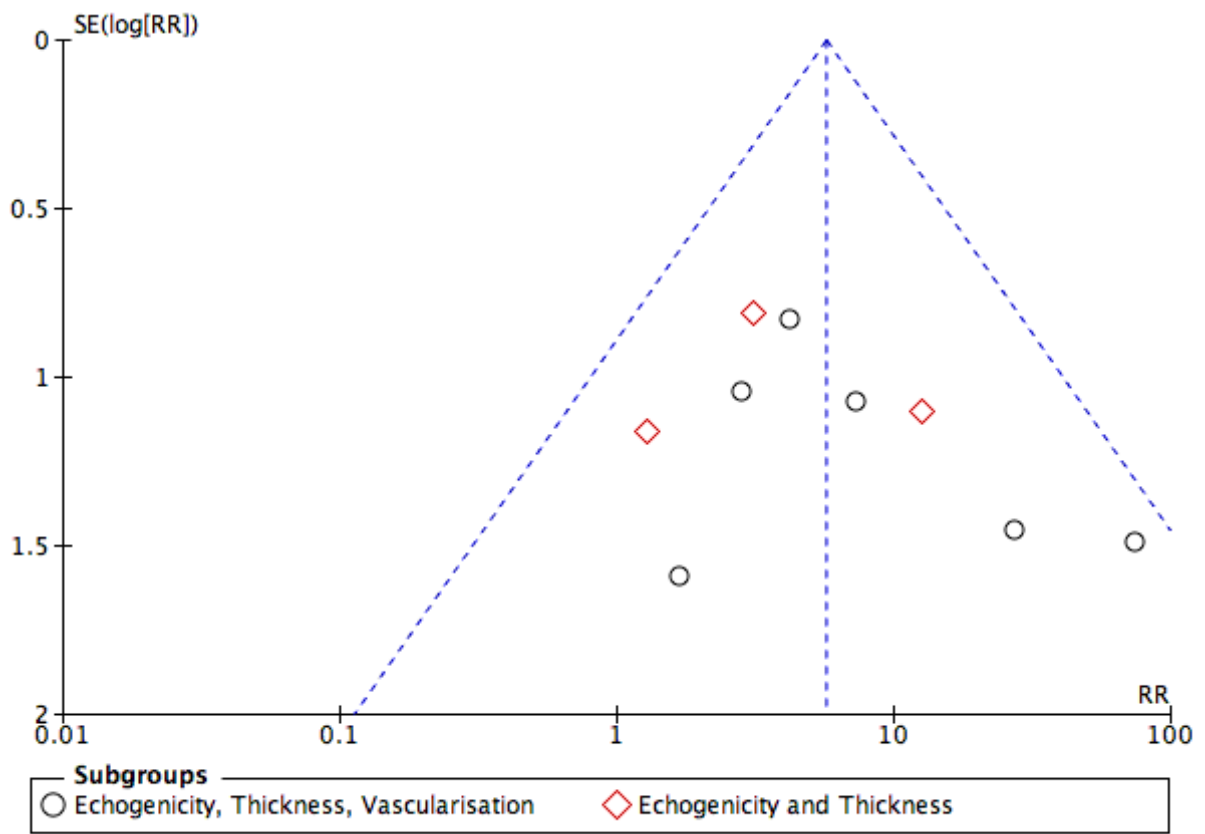
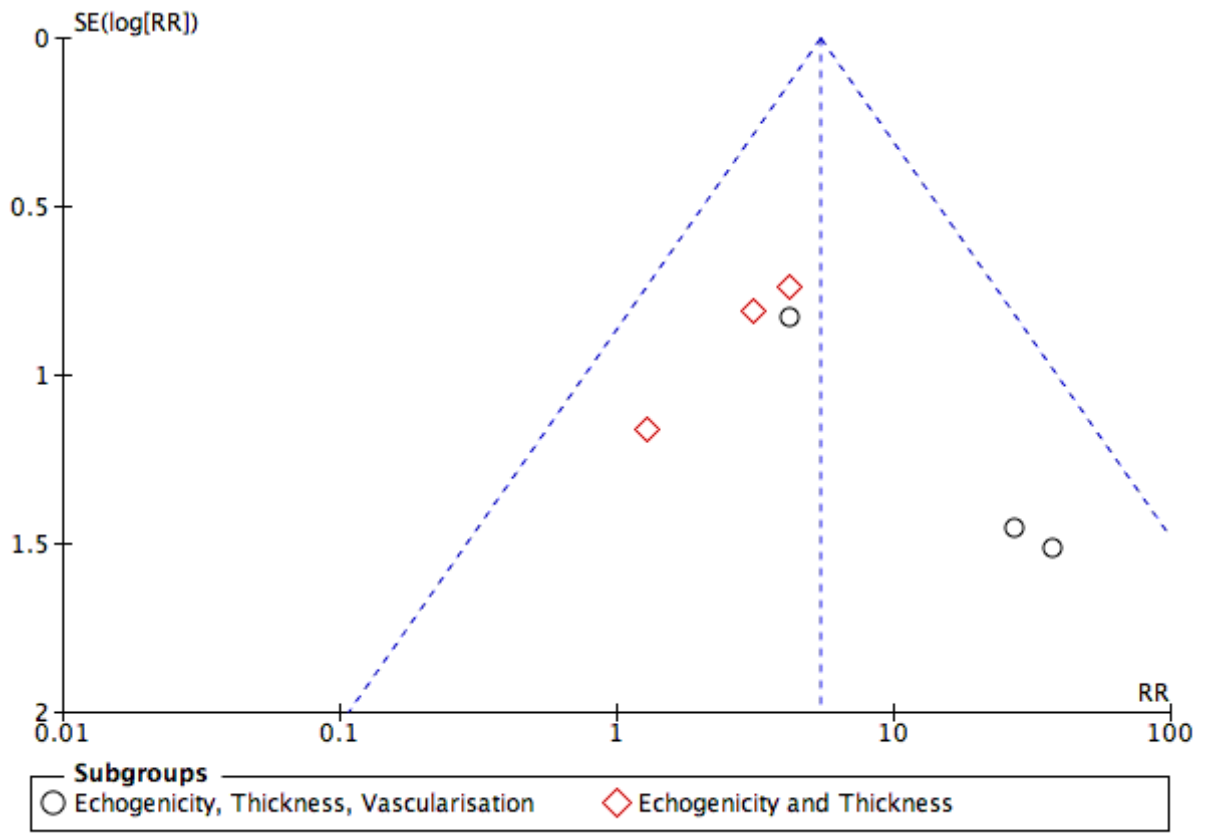


Figure 7



Acknowledgements

This research was supported by an Australian Government Research Training Program Scholarship

References

- Abate M, Gravare-Silbernagel K, Siljeholm C, Di Iorio A, De Amicis D, Salini V, Werner S, Paganelli R. Pathogenesis of tendinopathies: inflammation or degeneration? *Arthritis Research & Therapy* 2009; 11:235-35.
- Ackermann PW, Renström P. Tendinopathy in sport. *Sports Health: A Multidisciplinary Approach* 2012; 4:193-201.
- Adhia DB, Bussey MD, Ribeiro DC, Tumilty S, Milosavljevic S. Validity and reliability of palpation-digitization for non-invasive kinematic measurement – A systematic review. *Manual Therapy* 2013; 18:26-34.
- Archambault JM, Wiley JP, Bray RC, Verhoef M, Wiseman DA, Elliot PD. Can sonography predict the outcome in patients with achillodynia? *J Clin Ultrasound* 1998; 26:335-39.
- Arnoczky SP, Lavagnino M, Egerbacher M. The mechanobiological aetiopathogenesis of tendinopathy: Is it the over-stimulation or the under-stimulation of tendon cells? *Int J of Exp Pathol* 2007; 88:217-26.
- Barrett E, McCreesh K, Lewis J. Reliability and validity of non-radiographic methods of thoracic kyphosis measurement: A systematic review. *Manual Therapy* 2014; 19:10-17.
- Boesen AP, Boesen MI, Torp-Pedersen S, Christensen R, Boesen L, Holmich P, Nielsen MB, Koenig MJ, Hartkopp A, Ellegaard K, Bliddal H, Langberg H. Associations between abnormal ultrasound color Doppler measures and tendon pain symptoms in badminton players during a season: A prospective cohort study. *Am J Sports Med* 2012; 40:548-55.

- Bonde JP, Mikkelsen S, Andersen JH, Fallentin N, Baelum J, Svendsen SW, Thomsen JF, Frost P, Thomsen G, Overgaard E, Kaergaard A. Prognosis of shoulder tendonitis in repetitive work: A follow up study in a cohort of Danish industrial and service workers. *Occup Environ Med* 2003; 60:e8.
- Brasseur J-L, Lucidarme O, Tardieu M, Tordeur M, Montalvan B, Parier J, Goux P, Gires A, Grenier P. Ultrasonographic rotator-cuff changes in veteran tennis players: The effect of hand dominance and comparison with clinical findings. *Eur Radiol* 2004; 14:857-64.
- Comin J, Cook JL, Malliaras P, McCormack M, Calleja M, Clarke A, Connell D. The prevalence and clinical significance of sonographic tendon abnormalities in asymptomatic ballet dancers: A 24-month longitudinal study. *Br J Sports Med* 2013; 47:89-92.
- Conn VS, Valentine JC, Cooper HM, Rantz MJ. Grey literature in meta-analyses. *Nurs Res* 2003; 52:256.
- Cook JL, Khan KM, Harcourt PR, Kiss ZS, Fehrmann MW, Griffiths L, Wark JD. Patellar tendon ultrasonography in asymptomatic active athletes reveals hypoechoic regions: A study of 320 tendons. Victorian Institute of Sport Tendon Study Group. *Clin J Sport Med* 1998; 8:73.
- Cook JL, Khan KM, Kiss ZS, Coleman BD, Griffiths L. Asymptomatic hypoechoic regions on patellar tendon ultrasound: A 4-year clinical and ultrasound followup of 46 tendons. *Scand J of Med Sci Sports* 2001; 11:321.
- Cook JL, Khan KM, Kiss ZS, Purdam CR, Griffiths L. Prospective imaging study of asymptomatic patellar tendinopathy in elite junior basketball players. *J Ultrasound Med* 2000; 19:473-9.

- Cook JL, Khan KM, Kiss ZS, Purdam CR, Griffiths L. Reproducibility and clinical utility of tendon palpation to detect patellar tendinopathy in young basketball players. *Br J Sports Med* 2001; 35:65.
- Cook JL, Purdam CR. Is tendon pathology a continuum? A pathology model to explain the clinical presentation of load-induced tendinopathy. *Br J Sports Med* 2009; 43:409.
- Cook JL, Rio E, Purdam CR, Docking SI. Revisiting the continuum model of tendon pathology: What is its merit in clinical practice and research? *Br J Sports Med* 2016; 50:1187-91.
- Coombes BK, Bisset L, Vicenzino B. Management of lateral elbow tendinopathy: One size does not fit all. *J Orthop Sports Phys Ther* 2015; 45:938-49.
- Critical Appraisal Skills Programme. 2017 CASP Cohort Study Checklist [online].
- Critical Appraisal Skills Programme. 2017 CASP Randomised Controlled Trials Checklist [online].
- de Jonge S, de Vos RJ, Van Schie HTM, Verhaar JAN, Weir A, Tol JL. One-year follow-up of a randomised controlled trial on added splinting to eccentric exercises in chronic midportion Achilles tendinopathy. *Br J Sports Med* 2010; 44:673.
- de Vos RJ, Weir A, Cobben LP, Tol JL. The value of power Doppler ultrasonography in Achilles tendinopathy: A prospective study. *Am J Sports Med* 2007; 35:1696-701.
- de Vos RJ, Weir A, Tol JL, Verhaar JAN, Weinans H, van Schie HTM. No effects of PRP on ultrasonographic tendon structure and neovascularisation in chronic midportion Achilles tendinopathy. *Br J Sports Med* 2011; 45:387-92.

Docking SI, Cook J. Pathological tendons maintain sufficient aligned fibrillar structure on ultrasound tissue characterization (UTC). *Scand J Med Sci Sports* 2016; 26:675-83.

Docking SI, Ooi C, Connell D. Tendinopathy: Is imaging telling us the entire story? *J Orthop Sports Phys Ther* 2015; 45:842-52.

Domenichini R, Pialat J-B, Podda A, Aubry S. Ultrasound elastography in tendon pathology: state of the art. *Skeletal Radiol* 2017; 46:1643-55.

Ellis R, Manuel T. Identifying tendon matrix changes with ultrasound imaging: A literature review and proposed ultrasound criteria for staging for tendinopathy. *Physiotherapy (United Kingdom)* 2015; 101:eS357.

Fleiss JL. *Statistical methods for rates and proportions*. New York: John Wiley, 1981.

Fredberg U, Bolvig L. Significance of ultrasonographically detected asymptomatic tendinosis in the patellar and Achilles tendons of elite soccer players. *Am J Sports Med* 2002; 30:488.

Fredberg U, Bolvig L, Andersen NT. Prophylactic training in asymptomatic soccer players with ultrasonographic abnormalities in Achilles and patellar tendons: the Danish Super League study. *Am J Sports Med* 2008; 36:451-60.

Fredberg U, Bolvig L, Pfeiffer-Jensen M, Clemmensen D, Jakobsen BW, Stengaard-Pedersen K. Ultrasonography as a tool for diagnosis, guidance of local steroid injection and, together with pressure algometry, monitoring of the treatment of athletes with chronic jumper's knee and Achilles tendinitis: A randomized, double-blind, placebo-controlled study. *Scand J Rheum* 2004; 33:94.

Fu SC, Rolf C, Cheuk YC, Lui PP, Chan KM. Deciphering the pathogenesis of tendinopathy: A three-stages process. *Sports Medicine, Arthroscopy, Rehabilitation, Therapy & Technology* 2010; 2:30.

- Giombini A, Dragoni S, Di Cesare A, Di Cesare M, Del Buono A, Maffulli N.
Asymptomatic Achilles, patellar, and quadriceps tendinopathy: A longitudinal clinical and ultrasonographic study in elite fencers. *Scand J Med Sci Sports* 2013; 23:311-16.
- Gisslén K, Alfredson H. Neovascularisation and pain in jumper's knee: A prospective clinical and sonographic study in elite junior volleyball players. *Br J Sports Med* 2005; 39:423-28.
- Gisslén K, Gyulai C, Nordström P, Alfredson H. Normal clinical and ultrasound findings indicate a low risk to sustain jumper's knee patellar tendinopathy: A longitudinal study on Swedish elite junior volleyball players. *Br J Sports Med* 2007; 41:253-58.
- Goldsmith MR, Bankhead CR, Austoker J. Synthesising quantitative and qualitative research in evidence-based patient information. *J Epidemiol Community Health* 2007; 61:262.
- Grimaldi A, Mellor R, Nicolson P, Hodges P, Bennell K, Vicenzino B. Utility of clinical tests to diagnose MRI-confirmed gluteal tendinopathy in patients presenting with lateral hip pain. *Br J Sports Med* 2017; 51:519.
- Higgins JPT, Thompson SG, Deeks JJ, Altman DG. Measuring inconsistency in meta-analyses. *BMJ* 2003; 327:557.
- Hirschmüller A, Frey V, Konstantinidis L, Baur H, Dickhuth H-H, Südkamp NP, Helwig P. Prognostic value of Achilles tendon Doppler sonography in asymptomatic runners. *Med Sci Sports Exerc* 2012; 44:199-205.
- Hutchison A-M, Evans R, Bodger O, Pallister I, Topliss C, Williams P, Vannet N, Morris V, Beard D. What is the best clinical test for Achilles tendinopathy? *Foot and Ankle Surgery* 2013; 19:112.

- Ingwersen KG, Hjarbaek J, Eshoej H, Larsen CM, Vobbe J, Juul-Kristensen B. Ultrasound assessment for grading structural tendon changes in supraspinatus tendinopathy: an inter-rater reliability study. *BMJ* 2016; 6.
- Jhingan S, Perry M, O'Driscoll G, Lewin C, Teatino R, Malliaras P, Maffulli N, Morrissey D. Thicker Achilles tendons are a risk factor to develop Achilles tendinopathy in elite professional soccer players. *Muscles, Ligaments and Tendons Journal* 2011; 1:51-56.
- Kennelly J. Methodological approach to assessing the evidence, In: Handler A, Kennelly J, and Peacock N, eds. *Reducing racial/ethnic disparities in reproductive and perinatal outcomes: The evidence from population-based interventions*. Boston, MA: Springer US, 2011. 7-19.
- Khan KM, Cook JL, Kiss ZS, Visentini PJ, Fehrmann MW, Harcourt PR, Tress BW, Wark JD. Patellar tendon ultrasonography and jumper's knee in female basketball players: A longitudinal study. *Clin J Sport Med* 1997; 7:199-206.
- Khan KM, Cook JL, Taunton JE, Bonar F. Overuse tendinosis, not tendinitis part 1: A new paradigm for a difficult clinical problem. *The Physician and Sports Medicine* 2000; 28:38.
- Khan KM, Forster BB, Robinson J, Cheong Y, Louis L, Maclean L, Taunton JE. Are ultrasound and magnetic resonance imaging of value in assessment of Achilles tendon disorders? A two year prospective study. *Br J Sports Med* 2003; 37:149-53.
- Koenig MJ, Torp-Pedersen S, Boesen MI, Holm CC, Bliddal H. Doppler ultrasonography of the anterior knee tendons in elite badminton players: Colour fraction before and after match. *Br J Sports Med* 2010; 44:134-39.

- Lento P, Primack S. Advances and utility of diagnostic ultrasound in musculoskeletal medicine. *Current Reviews in Musculoskeletal Medicine* 2008; 1:24-31.
- Leung JLY, Griffith JF. Sonography of chronic Achilles tendinopathy: A case-control study. *J Clin Ultrasound* 2008; 36:27-32.
- Lewis J. Rotator cuff related shoulder pain: Assessment, management and uncertainties. *Manual Therapy* 2016; 23:57-68.
- Lewis J, McCreesh K, Roy J-S, Ginn K. Rotator cuff tendinopathy: Navigating the diagnosis-management conundrum. *J Orthop Sports Phys Ther* 2015; 45:923-37.
- Lewis JS. Rotator cuff tendinopathy. *Br J Sports Med* 2009; 43:236.
- Maffulli N, Khan KM, Puddu G. Overuse tendon conditions: Time to change a confusing terminology. *Arthroscopy* 1998; 14:840-43.
- Malliaras P, Cook J, Purdam C, Rio E. Patellar tendinopathy: Clinical diagnosis, load management, and advice for challenging case presentations. *J Orthop Sports Phys Ther* 2015; 45:887-98.
- Malliaras P, Purdam C, Maffulli N, Cook J. Temporal sequence of greyscale ultrasound changes and their relationship with neovascularity and pain in the patellar tendon. *Br J Sports Med* 2010; 44:944-47.
- Mapes-Gonnella T. The impact of education: Has the failure to standardize musculoskeletal sonography undermined its value? *Journal of Diagnostic Medical Sonography* 2013; 29:260-68.
- May S, Chance-Larsen K, Littlewood C, Lomas D, Saad M. Reliability of physical examination tests used in the assessment of patients with shoulder problems: A systematic review. *Physiotherapy* 2010; 96:179-90.

- May S, Littlewood C, Bishop A. Reliability of procedures used in the physical examination of non-specific low back pain: A systematic review. *Australian Journal of Physiotherapy* 2006; 52:91-102.
- McAuliffe S, McCreesh K, Culloty F, Purtill H, O'Sullivan K. Can ultrasound imaging predict the development of Achilles and patellar tendinopathy? A systematic review and meta-analysis. *Br J Sports Med* 2016; 50:1516.
- McCreesh K, Lewis J. Continuum model of tendon pathology - where are we now? *Int J Exp Pathol* 2013; 94:242-47.
- Moher D, Liberati A, Tetzlaff J, Altman DG. Preferred reporting items for systematic reviews and meta-analyses: The PRISMA statement. *BMJ* 2009; 339.
- Morrison A, Polisena J, Husereau D, Moulton K, Clark M, Fiander M, Mierzwinski-Urban M, Clifford T, Hutton B, Rabb D. The effect of English-language restriction on systematic review-based meta-analyses: A systematic review of empirical studies. *Int J Technol Assess Health Care* 2012; 28:138-44.
- Ooi C, Malliaras P, Schneider ME, Connell DA. Soft, hard, or just right: Applications and limitations of axial-strain sonoelastography and shear-wave elastography in the assessment of tendon injuries. *Skeletal Radiol* 2014; 43:1-12.
- Ooi C, Schneider M, Malliaras P, Counsel P, Connell D. Prevalence of morphological and mechanical stiffness alterations of mid Achilles tendons in asymptomatic marathon runners before and after a competition. *Skeletal Radiol* 2015; 44:1119-27.
- Plinsinga ML, Brink MS, Vicenzino B, van Wilgen CP. Evidence of nervous system sensitization in commonly presenting and persistent painful tendinopathies: A systematic review. *J Orthop Sports Phys Ther* 2015; 45:864-75.

- Rees JD, Maffulli N, Cook J. Management of tendinopathy. *Am J Sports Med* 2009; 37:1855-67.
- Rees JD, Stride M, Scott A. Tendons – time to revisit inflammation. *Br J Sports Med* 2014; 48:1553.
- Reeves ND, Maganaris CN, Ferretti G, Narici MV. Influence of 90-day simulated microgravity on human tendon mechanical properties and the effect of resistive countermeasures. *J Appl Physiol* 2005; 98:2278.
- Rio E, Moseley L, Purdam C, Samiric T, Kidgell D, Pearce AJ, Jaberzadeh S, Cook J. The pain of tendinopathy: Physiological or pathophysiological? *Sports Med* 2014; 44:9-23.
- Rosengarten SD, Cook JL, Bryant AL, Cordy JT, Daffy J, Docking SI. Australian football players' Achilles tendons respond to game loads within 2 days: An ultrasound tissue characterisation (UTC) study. *Br J Sports Med* 2015; 49:183-87.
- Ryan M, Taunton J, Wong A. Favorable outcomes after sonographically guided intratendinous injection of hyperosmolar dextrose for chronic insertional and midportion achilles tendinosis. *AJR Am J Roentgenol* 2010; 194:1047-53.
- Ryan M, Wong A, Rabago D, Lee K, Taunton J. Ultrasound-guided injections of hyperosmolar dextrose for overuse patellar tendinopathy: A pilot study. *Br J Sports Med* 2011; 45:972.
- Ryu J, Jeong WK. Current status of musculoskeletal application of shear wave elastography. *Ultrasonography (Seoul, Korea)* 2017; 36:185.
- Scase E, Purdam C, Cook J. Matching tendinopathy stage with efficacious intervention. *Soundeffects* 2011:14-18.

- Scott A, Ashe M. Common tendinopathies in the upper and lower extremities. *Current Sports Medicine Reports* 2006; 5:233-41.
- Scott A, Backman LJ, Speed C. Tendinopathy: Update on pathophysiology. *J Orthop Sports Phys Ther* 2015; 45:833-41.
- Scott A, Docking S, Vicenzino B, Alfredson H, Zwerver J, Lundgreen K, Finlay O, Pollock N, Cook JL, Fearon A, Purdam CR, Hoens A, Rees JD, Goetz TJ, Danielson P. Sports and exercise-related tendinopathies: A review of selected topical issues by participants of the second International Scientific Tendinopathy Symposium (ISTS) Vancouver 2012. *Br J Sports Med* 2013; 47:536.
- Smidt N, Assendelft W, Arola H, Malmivaara A, Green S, Buchbinder R, van Der Windt D, Bouter L. Effectiveness of physiotherapy for lateral epicondylitis: A systematic review. *Ann Med* 2003; 35:51-62.
- Stevens SS. On the theory of scales of measurement. *Science* 1946; 103:677.
- Visnes H, Tegnander A, Bahr R. Ultrasound characteristics of the patellar and quadriceps tendons among young elite athletes. *Scand J Med Sci Sports* 2015; 25:205-15.
- Voss PH, Rehfues EA. Quality appraisal in systematic reviews of public health interventions: An empirical study on the impact of choice of tool on meta-analysis. *J Epidemiol Community Health* 2013; 67:98.
- Warden SJ, Kiss ZS, Malara FA, Ooi ABT, Cook JL, Crossley KM. Comparative accuracy of magnetic resonance imaging and ultrasonography in confirming clinically diagnosed patellar tendinopathy. *Am J Sports Med* 2007; 35:427.

Westacott D, Minns J, Foguet P. The diagnostic accuracy of magnetic resonance imaging and ultrasonography in gluteal tendon tears: A systematic review. *Hip International* 2011; 21:637-45.

Figure Captions List

Figure 1: Preferred Reporting Items for Systematic Reviews and Meta-analysis (PRISMA) flow diagram.

Figure 2: Meta-analysis results for studies using ultrasound imaging (US) to predict symptomatic Achilles and patellar tendinopathy.

Figure 3: Meta-analysis results comparing prediction of symptomatic Achilles and patellar tendinopathy using 3 ultrasound imaging (US) defined parameters and 2 US defined parameters.

Figure 4: Meta-analysis results comparing prediction of symptomatic patellar tendinopathy using 3 ultrasound imaging (US) defined parameters and 2 US defined parameters.

Figure 5: Funnel plot analysis of study bias for prediction of Achilles and patellar tendinopathy using ultrasound imaging (US).

Figure 6: Funnel plot analysis of study bias for prediction of Achilles and patellar tendinopathy using 3 ultrasound imaging (US) defined parameters and 2 US defined parameters.

Figure 7: Funnel plot analysis of study bias for prediction of patellar tendinopathy using 3 ultrasound imaging (US) defined parameters and 2 US defined parameters.